

# 9

## Abnormal Uterine Bleeding in the Premenopausal Period

Heleen van Beekhuizen

---

### INTRODUCTION

Abnormal uterine bleeding (AUB) is a very frequent symptom in women. The prevalence of AUB is estimated at 12% in the general population and increases with age, reaching 24% in those aged 36–40 years. When it is a single episode of irregular blood loss in non-pregnant women, it is most of the time harmless, but it can also be a first sign of serious pathology such as cancer of the cervix. For this reason it is important to do a full gynecological history, a speculum examination and a vaginal examination in all women with AUB.

For practical purposes it is important to rule out (unrecognized) pregnancy problems or infection in AUB of short duration. A longer duration of AUB points to more structural abnormalities like fibroids, polyps or malignancies.

This chapter will describe the problems and how to establish the diagnosis. A flow chart for abnormal uterine bleeding will be introduced. In Chapter 20 appropriate treatment of abnormal uterine bleeding will be explained. For bleeding after the menopause, please see Chapter 10.

### Definition

Terms like menorrhagia, metrorrhagia, menometrorrhagia should be abolished as their definitions differ from region to region. It is better to speak of 'abnormal uterine bleeding':

- A *normal cycle* is between 24 and 35 days with a period of <7 days. The main menstrual blood flow during a period is 35 ml with 65% of women losing <60 ml each period.
- *Menorrhagia*: regular cycle but blood loss >80 ml per cycle<sup>1</sup>.

- *Metrorrhagia*: bleeding at irregular intervals.
- *Intermenstrual blood loss (IBL)*: irregular blood loss during a normal menstrual cycle.

### Chronic abnormal uterine bleeding

Chronic AUB is defined by the International Federation of Gynecology and Obstetrics (FIGO) as bleeding from the uterine corpus that is abnormal in volume, regularity, and/or timing, and has been present for the majority of the past 6 months in non-pregnant women.

### Acute abnormal uterine bleeding

Acute AUB is defined as an episode of heavy bleeding in non-pregnant women that, in the opinion of the clinician, is of sufficient quantity to require immediate intervention to prevent further blood loss. Acute AUB may present in the context of existing chronic AUB or might occur without such a history.

### CAUSES OF UTERINE BLEEDING

FIGO have developed a classification system for AUB (Table 1)<sup>2</sup>.

- *Polyps and pediculated fibroids*: (generally) benign growths of uterine muscle (fibroids) or endometrium (polyps).
- *Adenomyosis*: the role of adenomyosis in AUB is not clear yet. Adenomyosis describes the presence of endometrial tissue in the myometrium. The sonographic appearance of adenomyosis is partly related to the absolute presence of endometrial tissue in the myometrium and partly due to the related myometrial hypertrophy<sup>2</sup>.
- *Leiomyoma* (fibroids): benign growths of the myometrium (see Chapter 19).

**Table 1** FIGO classification system of abnormal uterine bleeding. PALM refers to structural abnormalities causing the abnormal bleeding, COEIN are non-structural causes

<b>P</b> Polyps	<b>C</b> Coagulopathy
<b>A</b> Adenomyosis	<b>O</b> Ovulatory dysfunctions
<b>L</b> Leiomyoma	<b>E</b> Endometrial
<b>M</b> Malignancy or hyperplasia	<b>I</b> Iatrogenic
	<b>N</b> Not yet classified

- *Malignancies*: especially cervical and uterine cancer (endometrial cancer or sarcoma, see Chapter 29) or hyperplasia. Granulosa cell tumors (see Chapter 28) of the ovaries produce estrogen and cause endometrial hyperplasia and AUB and postmenopausal vaginal bleeding.
- *Coagulopathy*: abnormal bleeding tendencies are present in around 13% of women with heavy menstrual bleeding.
- *Ovarian dysfunction (formerly dysfunctional uterine bleeding or DUB)*. The term ovarian dysfunction (OD) is used when hormonal imbalance is present. Common groups affected by OD are:
  - Young girls and perimenopausal women: both groups have anovulatory cycles (cycles without an ovulation). In long-term anovulation unopposed estrogen stimulation (with lack of progesterone) stimulates the endometrium to become hyperplastic. For menstrual cycle see Chapter 16 on subfertility.
  - Patients with obesity or extreme weight loss. In obesity peripheral fat tissue produces estrogen and morbidly obese women have a high level of estrogen that disturbs the menstrual cycle. Weight loss and emaceration can lead to anovulatory cycles and cause irregular periods
- *Endometrial causes* of AUB are:
  - A primary disorder of mechanisms regulating local endometrial ‘hemostasis’ itself: endometrial hemostasis is a very complex process and local hormonal imbalance in the prostaglandin mechanism can cause AUB.
  - Endometrial hyperplasia is a precursor to endometrial cancer and is classified as simplex or complex and with or without atypia. The presenting symptom is most often AUB. Endometrial hyperplasia with atypia is most

likely to progress to endometrial cancer (in about 25–40%) and should be treated surgically. When no atypia is present conservative treatment with Mirena® intrauterine device (IUD) or cyclic progestogens (medroxyprogesterone acetate (10mg/day for 12–14 days in the luteal phase of the cycle for 3 months), and repeated sampling is justified.

- Cervical ectopia or ectropion can cause spotting and postcoital bleeding (often in young women or pill users).
- Infections: Sexually transmitted infections (STIs) like chlamydia, urogenital schistosomiasis or genital tuberculosis.
- *Iatrogenic causes* of AUB are:
  - Anticonceptives like combined oral contraceptives, IUDs.
  - Tricyclic antidepressants like amitriptyline may cause AUB.
- *(Unrecognized) pregnancy (complications)* like miscarriage, ectopic pregnancy and molar pregnancy can cause bleeding and are sometimes mistaken for AUB.

### HISTORY TAKING

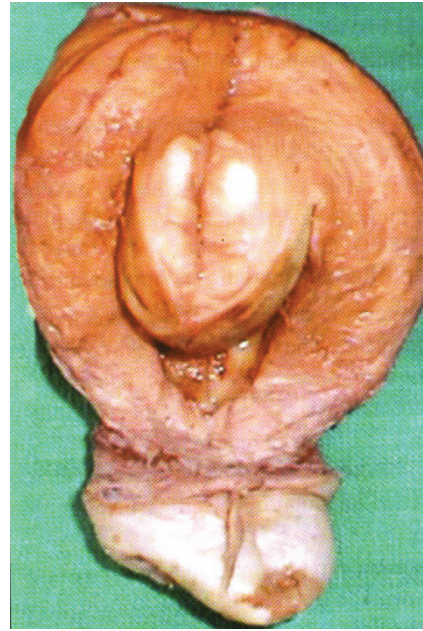
- Duration of complaints (primary/secondary, how many months/years). Primary AUB starts from the first period, secondary AUB starts later in the reproductive period.
- Duration of periods and regularity of the cycle.
- Fever, discharge and abdominal pain can be a sign of STI. Cervical cancer is often accompanied by foul-smelling discharge and ectopic pregnancy by pain!
- Swelling in the abdomen is a symptom of fibroids and ovarian masses but also of unrecognized pregnancy. Ask about fetal movements!
- Easy bleeding tendency. Some women have inherited bleeding disorders. They often have a history of prolonged bleeding during surgery, trauma or childbirth. It is difficult in low-resource settings to establish the exact diagnosis but you can treat heavy periods in these women the same as in women without bleeding disorders (see Chapter 20)<sup>3,4</sup>. Make women with inherited bleeding disorders aware that it is important to deliver in a hospital with blood transfusion possibilities!
- Endocrine disorders like polycystic ovary syndrome (POC) (see Chapter 16 on subfertility),

hypothyroidism, hyperthyroidism and hyperprolactinemia. Signs of hypothyroidism are irregular periods with weight gain, lethargy, obstipation, hair loss (especially at the eyebrows) and a dry skin. Signs of hyperthyroidism are sweating, menorrhagia, palpitations, weight loss, irritability and tremor. Signs of hyperprolactinemia are bilateral galactorrhea (milk from the nipples), amenorrhea, anovulation and (when caused by macroadenoma) headache and disturbance of visual fields (see Chapter 16).

- Use of contraceptives: many women using progesterone contraceptives such as Depo-Provera<sup>®</sup>, Implanon<sup>®</sup> and levonogestrel (LNG) IUD (Mirena<sup>®</sup>) have irregular blood loss<sup>5</sup>. Also many women with prolonged combined oral contraceptive use can face a period of spotting and postcoital bleeding.
- Sexual history: STIs? Sexual abuse? Is pregnancy possible?
- Dates of the two last periods and duration of bleeding. Are blood clots present during the period or flooding?
- IBL: in chlamydia often IBL (spotting) occurs.

### EXAMINATION

- Signs of anemia.
- Signs of pregnancy: abdominal distention, blue, soft cervix, bigger breasts and nipples. If in doubt: do a pregnancy test.
- Obesity or emaciation.
- Speculum examination: to establish that blood loss is from the uterus (and not from the cervix or vagina) and to look for signs and symptoms of:
  - Cervical carcinoma (see Chapter 26 on cervical cancer)? An abnormal cervix can also be seen in genital schistosomiasis.
  - Vaginal discharge?
  - Cervicitis (see Chapter 17 on STI)?
  - Cervical ectopia/ectropion? This can be caused by *Chlamydia* but is also physiological in young fertile women and under OC. After ruling out (pre-) malignancy and chlamydia infection of the cervix you can use cryocoagulation in physiological ectropion to reduce the bleeding.
  - Presence of grainy sandy patches – alterations are considered to be characteristic of schistosomiasis in the cervix<sup>6</sup>.



**Figure 1** A fibroid in the uterine cavity after hysterectomy

If possible perform a test for pre-stadia of cervical cancer like a human papillomavirus (HPV) test or a visual inspection with acetic acid (VIA), see Chapter 26.

- PVE: fibroids, pelvic masses, cervical motion tenderness (Figure 1).

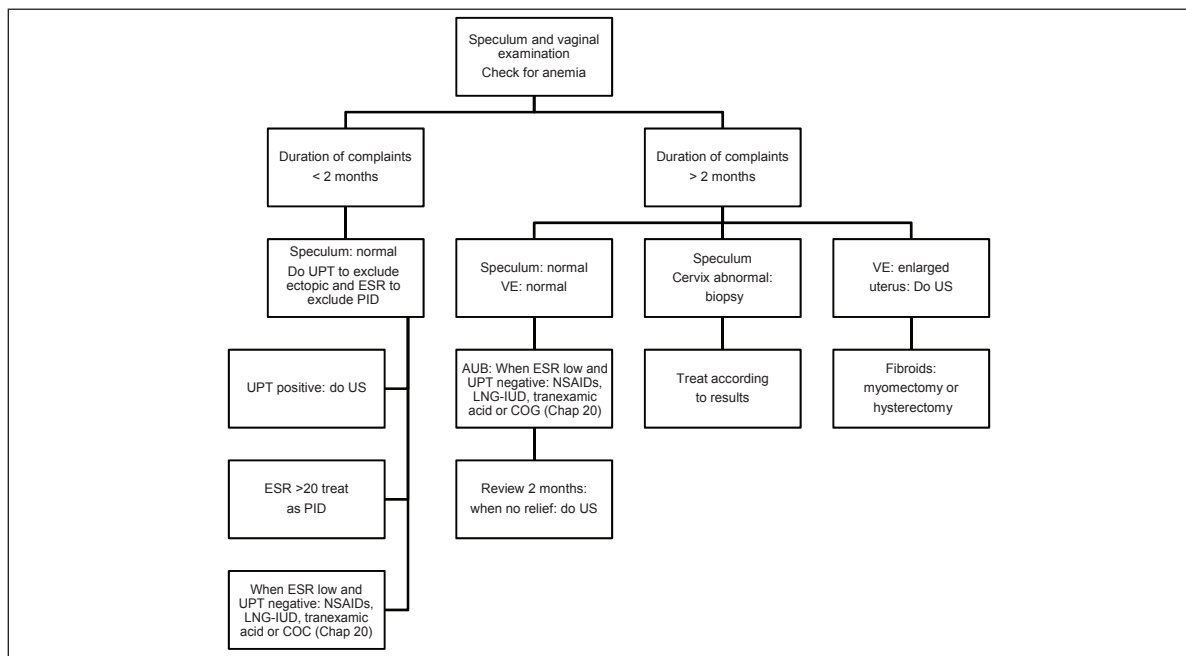
Most of the time you can make the diagnosis and treat the patient after history taking and physical examination and you do not need (to refer for) extra investigations. Remember it is important to rule out curable life-threatening diseases like ectopic pregnancy, cervical cancer and STIs as soon as possible. If you do not have facilities for extra investigations and tests and your history taking and physical examination were reassuring you can start treatment (see Chapter 20) and review the patient after 2 months. If she is well and irregular blood loss has stopped, there is no need for additional testing. If at review the patient still has irregular blood loss, refer her for extra diagnostic investigations and tests.

### DIAGNOSTIC INVESTIGATIONS AND TESTS THAT CAN HELP

- Hemoglobin (Hb): check for anemia. Severe anemia is an indicator of higher blood loss.

GYNECOLOGY FOR LESS-RESOURCED LOCATIONS

- Erythrocyte sedimentation rate (ESR) is prolonged in case of infection (and cancer). This is a simple test that can be performed in many small laboratories.
- Pregnancy test (UPT) on indication (recent start of AUB). The UPT is positive in normal, non-viable (missed abortion), ectopic and molar pregnancies and after recent abortion.
- Urine test or vaginal swab for schistosomiasis in endemic areas. Urine test is frequently false-negative and the sensitivity of the vaginal swab is unknown. A biopsy is probably more sensitive to detect schistosomiasis.
- Ultrasound: timing of ultrasound is important if you want to evaluate the endometrial thickness. The best time to perform an ultrasound is just after the period stopped. In ultrasound you can detect thickened endometrium (polyps, hyperplasia), fibroids, pregnancy and ovarian masses. A useful cut-off point for thickened endometrium (measured just after the menstruation stopped) is around 8mm in premenopausal women<sup>7</sup>. In ultrasound you can also see signs of pelvic inflammatory disease (PID) such as intra-abdominal fluid and abscesses. An ultrasound in case of ruptured ectopic pregnancy will also show free abdominal fluid.
- In thickened endometrium on normal ultrasound, saline infusion ultrasound<sup>8</sup> can be helpful (see how to do this in Chapter 1 on gynecological examination). It is easy to differentiate between endometrial polyps and general thickened endometrium. It does not tell you whether the found abnormalities are benign or malignant.
- Biopsy for histology if suspicion of cervical or endometrial carcinoma. A cervical biopsy can be obtained using a special cervical biopsy forceps. A biopsy will detect cervical schistosomiasis in approximately 50% of the patients and almost 100% of cervical cancer patients. For endometrial sampling (do this in perimenopausal women with thickened endometrium on ultrasound after their period) you could use the smallest cannula of a manual vacuum aspiration (MVA) set (see Chapter 13) or perform a dilatation and curettage (D&C). The big advantage of a MVA is that you can perform this without anesthesia in most women. The advantage of D&C is that if AUB is caused by polyps the D&C can be therapeutic.



**Figure 2** Flowchart for management of premenopausal abnormal uterine bleeding (AUB). COC, combined oral contraceptive; DUB, dysfunctional uterine bleeding; ESR, erythrocyte sedimentation rate; NSAIDs, non-steroidal anti-inflammatory drugs; UPT, urine for pregnancy test; US, ultrasound; VE, bimanual vaginal examination

- Hysteroscopy is an advanced diagnostic test: with a scope you can inspect the inside of the uterus. In many low-resource settings this is not available yet (see Chapter 1).
- HPV or VIA tests to screen for precursor lesions of cervical cancer (see Chapter 26).

### TREATMENT OF ABNORMAL UTERINE BLEEDING

Treatment of AUB is described in chapters about the causes of AUB: fibroids and cervical cancer, and in Chapter 20 about the treatment of functional AUB.

### FLOWCHART: PREMENOPAUSAL ABNORMAL BLEEDING

In the flowchart history taking (duration of the problem) and examination (speculum examination and vaginal examination) are used to stratify to appropriate treatment (Figure 2). But keep in mind: some women with a short duration of complaints might have fibroids or cervical cancer!

### REFERENCES

1. Marret H, Fauconnier A, Chabbert-Buffet N, *et al.* Clinical practice guidelines on menorrhagia: management of abnormal uterine bleeding before menopause. *Eur J Obstet Gynecol Reprod Biol* 2010;152:133–7
2. Munro MG, Critchley HO, Broder MS, Fraser IS. FIGO classification system (PALM-COEIN) for causes of abnormal uterine bleeding in nonpregnant women of reproductive age. *Int J Gynaecol Obstet* 2011;113:3–13
3. Madkour A, Finkenzeller D. Abnormal uterine bleeding. In: Hurt KJ, Guile MW, Bienstock JL, Fox HE, Wallach EE, eds. *The Johns Hopkins Manual of Gynecology and Obstetrics*, 4th edn. Philadelphia: Wolters Kluwer, Lippincott, Williams & Wilkins, 2011;476–85
4. Shankar M, Lee CA, Sabin CA, *et al.* von Willebrand disease in women with menorrhagia: a systematic review. *BJOG* 2004;111:734–40
5. Gallos ID, Shehmar M, Thangaratinam S, *et al.* Oral progestogens vs levonorgestrel-releasing intrauterine system for endometrial hyperplasia: a systematic review and metaanalysis. *Am J Obstet Gynecol* 2010;203:547e1–10
6. World Health Organization. Report of an informal working group on urogenital schistosomiasis and HIV transmission. WHO/HTM/NTD/PCT/2010.5. Geneva: WHO, 2009
7. Ozdemir S, Celik C, Gezginc K, *et al.* Evaluation of endometrial thickness with transvaginal ultrasonography and histopathology in premenopausal women with abnormal vaginal bleeding. *Arch Gynecol Obstet* 2009; 282:395–9
8. de Kroon CD, de Bock GH, Dieben SW, Jansen FW. Saline contrast hysterosonography in abnormal uterine bleeding: a systematic review and meta-analysis. *BJOG* 2003;110:938–47