

# 10

## Uterine Bleeding in the Postmenopausal Period

Heleen van Beekhuizen

---

### INTRODUCTION

Vaginal bleeding in the postmenopausal period is always abnormal and needs detailed history taking, speculum examination and bimanual vaginal examination. Many women need additional tests like visual inspection with acetic acid (VIA) and ultrasound to rule out cervical (pre)malignancy and endometrial cancer or bleeding from other sources (rectal, urinary tract).

### Definition

A woman is postmenopausal if her periods have stopped for 12 months.

### CAUSES OF POSTMENOPAUSAL VAGINAL BLEEDING

- *Atrophy*: the cells of the urogenital system have estrogen receptors. After the menopause the urogenital system becomes atrophic and the vagina becomes dry, pale, narrow, loses its elasticity and bleeding can occur. Other symptoms are dyspareunia (pain during intercourse), urine incontinence or urinary frequency (frequent need to urinate) or vaginal discharge.
- *Urogenital prolapse*: this can cause friction and ulceration leading to postmenopausal blood loss.
- *Forgotten intrauterine device (IUD)*: sometimes women present with an old IUD in the uterus for a long period. This can cause vaginal bleeding due to infection. Treatment is simple: remove the IUD.
- *Hyperplastic endometrium*: atypical hyperplasia can be a pre-stadium of endometrial cancer and is caused by unopposed estrogen stimulation (without progesterone that causes withdrawal

bleeding) of the endometrium. It is more frequent in women with obesity or a long history of polycystic ovary syndrome (see Chapter 16 on subfertility) and anovulatory cycles. Hyperplasia with atypical cytological features is more likely to progress into uterine cancer (25–40%) than hyperplasia without atypical cytological features that becomes malignant in only a few patients.

- *Endometrium polyp*: this is a benign growth of the inside lining of the uterus, the endometrium. Sometimes the polyp is ‘born’ and visible on speculum examination.
- *Cervical cancer*: bleeding and foul smelling discharge are common symptoms. In advanced cases pelvic pain is prominent.
- *Endometrial cancer*: blood loss is often the first sign. It is very uncommon in women below the age of 40 years, but in all postmenopausal women with bleeding problems it should be considered.
- *Uterine sarcoma*: a highly malignant tumor of the uterus is more common in black women. Blood loss, pain and abdominal mass are the most frequent symptoms. Sarcoma can present pre- or postmenopausal but is rare.
- *Granulosa cell tumors of the ovaries*: these produce estrogen and cause endometrial hyperplasia and dysfunctional uterine bleeding (DUB) or postmenopausal vaginal bleeding.
- *Urogenital schistosomiasis*: this can cause abnormal bleeding in postmenopausal women and can mimic cervical cancer.

### HISTORY TAKING

- Age of menopause and duration of postmenopause.

- Pregnancies and periods before menopause (regular cycles?).
- Duration and frequency of bleeding.
- Symptoms of atrophy (dryness of the vagina, dyspareunia, dysuria) or prolapse present?
- Vaginal discharge.
- Abdominal swelling or pain.
- Sexual history: sexually transmitted infections (STIs)?
- Contraception before menopause (IUD)?

### EXAMINATION

- Obesity: women with morbid obesity [body mass index (BMI) >30; see Chapter 8 on how to calculate BMI] have a high level of estrogen.
- Speculum examination:
  - Signs of atrophy: pale, dry vagina sometimes with petechia (small red spots caused by sub-mucosal bleeding).
  - Prolapse with pressure sores?
  - Cervical carcinoma?
  - Vaginal discharge? Cervicitis?
  - Endometrial polyp visible in vagina?
  - If possible perform a test for pre-stadia of cervical cancer like a human papillomavirus (HPV) test or a VIA; see Chapter 26.
  - Presence of grainy sandy patches – alterations are considered to be characteristic of schistosomiasis in the cervix.
  - IUD thread.
- PVE: fibroids or pelvic masses? If you suspect advanced cervical carcinoma do a rectal examination as described in Chapter 1.

If you cannot find a plausible benign cause of postmenopausal blood loss the woman should undergo two tests: first an ultrasound to measure the thickness of the endometrium and to look for pelvic masses and secondly a test to exclude a premalignancy of the cervix (HPV or VIA).

### ADDITIONAL TESTS

- HPV or VIA tests to screen for pre-stadia of cervical cancer (see Chapter 26). If you work in a facility in which a PAP smear can be made this is a useful test in postmenopausal bleeding; you can detect pre-stadia of cervical cancer as well as the presence of (abnormal) endometrium cells. In postmenopausal women presence of endo-

metrium cells in a PAP smear is abnormal and needs endometrial tissue sampling (see below).

- Ultrasound: you can detect thickened endometrium (polyps, hyperplasia, endometrial cancer), fibroids and ovarian masses. A useful cut-off point for thickened endometrium is around 3–4 mm in postmenopausal women.
- Biopsy for histology if suspicion of cervical or endometrial carcinoma. A cervical biopsy can be obtained using a special cervical biopsy forceps and can detect cervical cancer in almost 100% and genital schistosomiasis in about 50%. For endometrial sampling (do this in postmenopausal women with thickened endometrium >3–4 mm on ultrasound) you could use the smallest cannula of a manual vacuum aspiration (MVA) set (see Chapter 6) or perform a dilatation and curettage (D&C). The big advantage of a MVA is that you can perform this without anesthesia in most women. The advantage of D&C is that if postmenopausal blood loss is caused by endometrium polyps the D&C can be therapeutic. Make sure you can send the sample to a place where histology can be done within a reasonable time.
- Hysteroscopy is an advanced diagnostic test: with a scope you can inspect the inside of the uterus. In many low-resource settings this is not available yet (see Chapter 1).

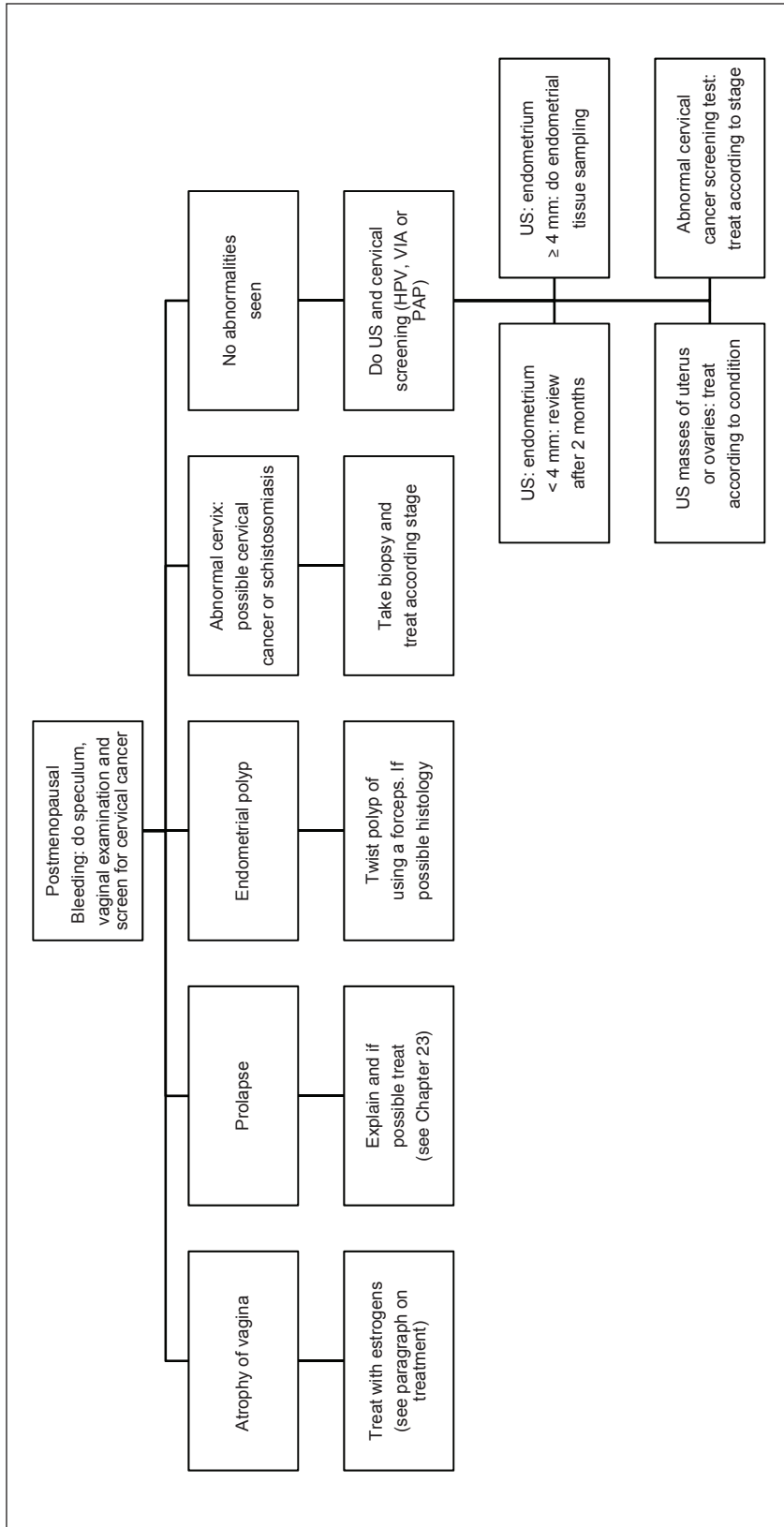
### TREATMENT

Endometrial malignancies need a hysterectomy with removal of ovaries (see Chapter 26 and Chapter 19 for TAH; Chapter 20 explains how to do a vaginal hysterectomy).

Hyperplasia with atypia needs a hysterectomy while hyperplasia without atypia can best be treated with a levonorgestrel (LNG)-IUD (Mirena®). Second-best therapy is oral progestogens like medroxyprogesterone acetate (10 mg/day for 3 months). In both cases repeat the sampling of the endometrium after 3 months. When performing an MVA after 3 months you can leave the IUD *in situ!*

Polyps protruding through the cervix can be grasped with a sponge-holding forceps and you can twist them off.

Atrophy of the vagina can be treated with topical estrogen cream, for example estriol cream 2–3 times a week.



**Figure 1** Flowchart for management of postmenopausal bleeding. PAP, cytological smear for detection of pre-stadia of cervix cancer; HPV, human papilloma virus test; US, ultrasound; VIA, visual inspection of cervix with acetic acid

For granulosa cell cancer, please see Chapter 28 and for prolapse Chapter 23.

**FLOWCHART: POSTMENOPAUSAL BLEEDING**

All women with postmenopausal bleeding should have detailed history taking and full gynecological examination (as in Chapter 1): do speculum, vaginal examination and screen for pre-stadia of cervical cancer (Figure 1).

**FURTHER READING**

Marret H, Fauconnier A, Chabbert-Buffet N, *et al.* Clinical practice guidelines on menorrhagia: management of abnormal uterine bleeding before menopause. *Eur J Obstet Gynecol Reprod Biol* 2010;152:133–7

World Health Organization. Report of an informal working group on urogenital schistosomiasis and HIV transmission. WHO/HTM/NTD/PCT/2010.5. Geneva: WHO, 2009

Kaur J, Dey P, Saha SC, *et al.* Cervical cytology in patients with postmenopausal bleeding. *Diagn Cytopathol* 2009; 38:496–8

Timmermans A, Opmeer BC, Khan KS, *et al.* Endometrial thickness measurement for detecting endometrial cancer in women with postmenopausal bleeding: a systematic review and meta-analysis. *Obstet Gynecol* 2010;116:160–7

Gallos ID, Shehmar M, Thangaratinam S, *et al.* Oral progestogens vs levonorgestrel-releasing intrauterine system for endometrial hyperplasia: a systematic review and meta-analysis. *Am J Obstet Gynecol* 2010;203:547e1–10