

# The Pelvic Pressure Pack and the Uterovaginal Balloon System

G. A. Dildy III

---

When pharmacologic and conservative surgical interventions fail to correct postpartum hemorrhage (PPH), hysterectomy most often becomes the option of last resort<sup>1</sup>. Contemporary reports on the incidence of obstetric hysterectomy range between 0.29 and 0.77 per 1000 deliveries<sup>2–7</sup>. Under these circumstances, a moderately busy obstetric unit with 4000 deliveries per year may perform as many as three emergency hysterectomies annually. This is especially true for women undergoing multiple repeat cesarean deliveries. Silver and colleagues reported in the Maternal–Fetal Medicine Units Network examination of 30,132 women undergoing cesarean delivery, that hysterectomy was required in 0.65% of first, 0.42% of second, 0.90% of third, 2.41% of fourth, 3.49% of fifth, and 8.99% of sixth or greater number cesarean deliveries<sup>8</sup>.

A systematic review of 981 cases of emergency postpartum hysterectomy reported an overall maternal mortality rate of 2.6%<sup>9</sup>. The maternal mortality associated with obstetric hysterectomy is higher (4–12.5%) in resource poor countries<sup>7,10</sup>, but not unheard of (0–4%) in developed areas<sup>4,8,11</sup> for a number of reasons, often relating to the moribund condition of the patient when the operation commences, the difficulty of the procedure itself, particularly in the presence of factors which make the anatomy unclear, and the extent of the bleeding which may accompany the operation. Indeed, Clark and colleagues reported an average estimated blood loss of 3.5 liters during emergency obstetric hysterectomy<sup>12</sup>. Furthermore, as the original extent of bleeding may have been underestimated, thus delaying resuscitation, surgical intervention and administration of blood component therapy, uncontrollable hemorrhage may be the event that mandates the hysterectomy<sup>13–15</sup>. As recounted in several other chapters in this Textbook, severe hemorrhage and emergency hysterectomy are often accompanied by secondary coagulopathy. In the setting of acquired coagulopathy, posthysterectomy bleeding may continue despite secure surgical pedicles, much to the consternation of the surgeon and the members of the operating team.

Abdominal and pelvic postsurgical packing is an old concept and one that has been used to control hemorrhage from a variety of sources, including liver

trauma<sup>16</sup>, pre-eclampsia-induced hepatic rupture<sup>17</sup>, rectal cancer<sup>18</sup>, gynecologic cancer<sup>19</sup> and, more recently, retroperitoneal packing as a part of damage-control surgery for trauma-related pelvic fracture management<sup>20–22</sup>. Various packing methods have been described, such as the ‘bowel bag’<sup>19</sup> or packing with dry laparotomy packs<sup>23</sup>. These methods, however, require re-laparotomy after initial stabilization to remove the packing materials. Other reported methods for packing, albeit not requiring re-laparotomy but with limited cumulative obstetric experience, include transcutaneous placement of an inflated condom over a 22-Fr catheter<sup>24</sup> or ribbon gauze within a Penrose drain<sup>25</sup>.

In 1926, Logothetopoulos described a pack for the management of uncontrolled posthysterectomy pelvic bleeding<sup>26</sup>. This technique has subsequently been called the mushroom, parachute, umbrella, pelvic pressure, or Logothetopoulos pack. It is important to note that the pelvic pressure pack described is applied posthysterectomy, and it should not be confused, as it often is, with uterine packing<sup>27</sup>, or with various intra-uterine balloons for treatment of PPH due to uterine atony or placental site bleeding which are described in Chapters 47, 48 and 54 of this volume<sup>28–30</sup>.

The pelvic pressure pack controls hemorrhage from large raw surfaces, venous plexuses and inaccessible areas by exerting well distributed pressure, compressing bleeding areas against the bony and fascial resistance of the pelvis<sup>31,32</sup>. According to Parente and colleagues, several references to the pelvic pressure pack appeared in European medical journals during the decades following the original report<sup>31</sup>. The first reported cases appearing in the English literature were not until the 1960s, and these pertained specifically to gynecologic posthysterectomy hemorrhage<sup>31,32</sup>; since then, several case reports and a case series for obstetric posthysterectomy bleeding have been published. Table 1 summarizes these cases, 23 for control of gynecologic and 13 for control of obstetric posthysterectomy hemorrhage, with success rates of 100% and 85%, respectively. Admittedly, accurate success rates are difficult to determine based on rare cases collected retrospectively, with possible underreporting of unfavorable outcomes. Nonetheless, successful control

of severe hemorrhage appears to have been achieved in the majority of cases.

As seen in Figure 1, the pack is constructed by filling a bag (we prefer a sterile X-ray cassette drape, but other materials also have been described) with gauze rolls tied end-to-end (in this case, five 11.4 cm × 2.8 m Kerlix rolls), starting at the ‘dome’ of the pack (A), with the ‘tail’ of the gauze protruding from the ‘neck’ of the pack (B–D). Gauze should be removed, as visually indicated, from the pack before placement, in order to fit the true pelvis.

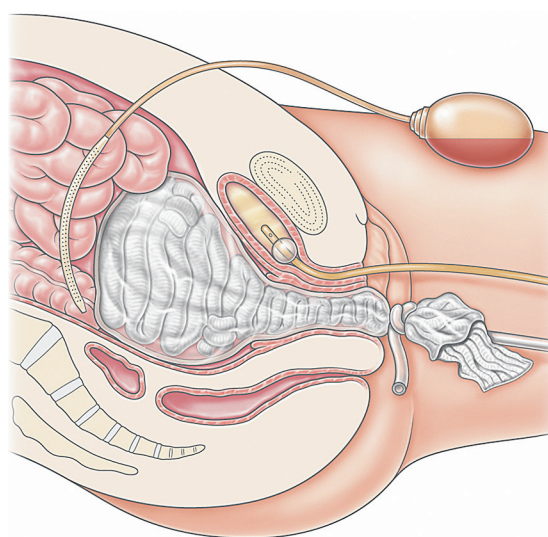
The pack is introduced transabdominally in the posthysterectomy patient into the pelvis (Figure 2), and the ‘neck’ is delivered transvaginally through the introitus by passing a surgical clamp from below through the open vaginal cuff. The surgeon should avoid trapping small bowel behind the pack. Traction and resulting pressure are applied to the pack by tying intravenous (IV) tubing to the neck of the pack and

suspending a 1-liter IV fluid bag off the foot of the bed. A 1-liter glass IV bottle and mild Trendelenburg position provide additional weight and traction if needed. The IV tubing or a cord can simply be hung over the foot of the bed, or over an orthopedic pulley attached to the foot of the bed. Compression of the pack can also be maintained by placing the ‘neck’ of the pack through a #80 doughnut pessary (not shown) applied flush against the perineum with a surgical clamp. However, caution must be taken to avoid perineal pressure necrosis.

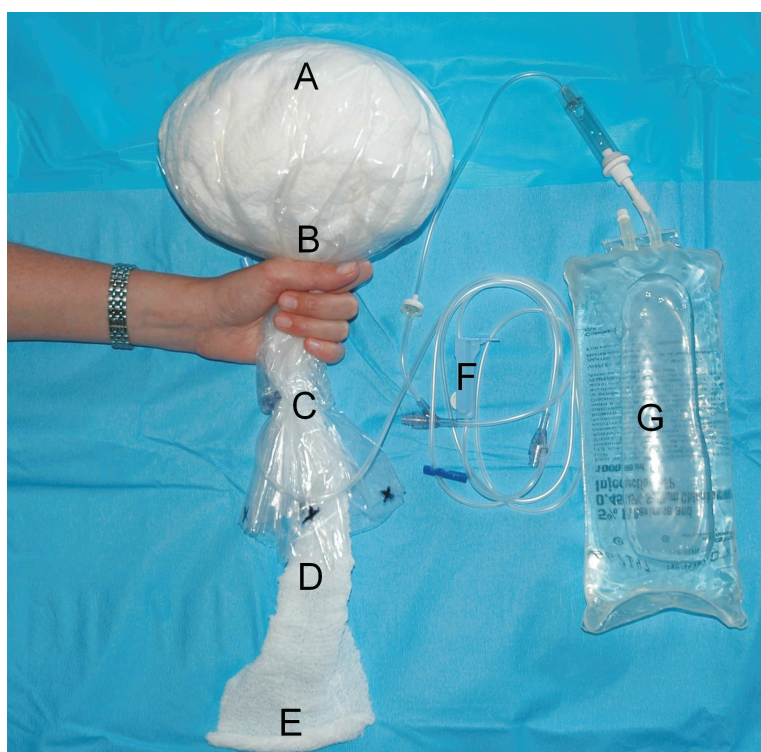
We advise placement of an intraperitoneal large-gauge closed-system (e.g. Jackson-Pratt) drain to

**Table 1** Summary of contemporary cases of the pelvic pressure pack for obstetric and gynecologic posthysterectomy hemorrhage. The success rate is defined as the pelvic pressure pack being the last intervention to control bleeding. Modified from Dildy *et al.*<sup>37</sup>

Series	Gynecology success rate	Obstetrics success rate
Parente, 1962 <sup>31</sup>	14/14	–
Burchell, 1968 <sup>32</sup>	8/8	–
Cassels, 1985 <sup>33</sup>	–	1/1
Robie, 1990 <sup>34</sup>	–	1/1
Hallak, 1991 <sup>35</sup>	–	1/1
Howard, 2002 <sup>36</sup>	–	1/1
Dildy, 2006 <sup>37</sup>	1/1	7/9
Total	23/23 (100%)	11/13 (85%)



**Figure 2** Diagram of the pelvic pressure pack *in situ*. See text for further explanation



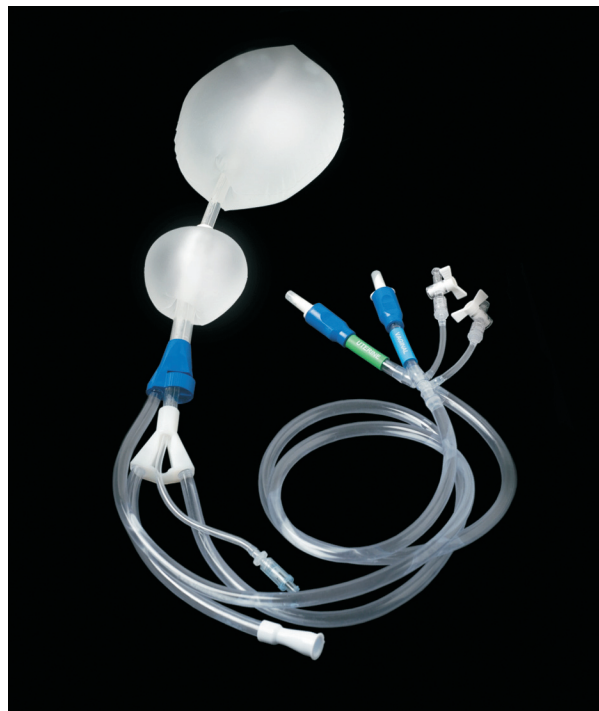
**Figure 1** Photograph of a pelvic pressure pack, as constructed from an X-ray cassette drape, sterile gauze rolls and an intravenous infusion set-up. See text for further explanation

monitor for postoperative bleeding. An indwelling urinary catheter allows monitoring of urine output and avoidance of urinary outflow obstruction. After stabilization of the patient, an attempt to remove the pack transvaginally is made by slowly removing the gauze rolls under intravenous sedation, to allow gradual decompression without inciting bleeding. The optimal time to leave the pack *in situ* varies, but extended placement has certain risks (see below). Usually transvaginal pack removal is successful, but in some cases the pack will require removal by re-laparotomy or with laparoscopic assistance.

In one study of trauma patients suffering intra-abdominal hemorrhage, Garrison and colleagues found that patients who experienced hypothermia, refractory hypotension, coagulopathy and acidosis required *early packing* if they were to survive<sup>38</sup>. Thus, packing should be considered early on when homeostasis is significantly altered. Febrile morbidity is very common in these critically ill postoperative patients who have already received massive blood component therapy and then have a foreign body placed into a contaminated operative field<sup>37</sup>. Prophylactic broad-spectrum antibiotics should be administered whenever a pelvic pressure pack is placed, and this regimen should be continued after pack removal until the patient is afebrile for at least 24–48 hours. Another study of abdominal trauma patients showed those packed for up to 72 hours had lower abscess, sepsis and mortality rates than those packed for more than 72 hours<sup>39</sup>. Thus pack removal should be accomplished as soon as possible following stabilization.

A newly developed medical device, the Belfort-Dildy Obstetrical Tamponade System, trade named the ebb™ Complete Tamponade System (Glenveigh Medical, LLC, Chattanooga, TN)\* was cleared by the US Food and Drug Administration (FDA) in 2010 for use in providing temporary control or reduction of *postpartum uterine bleeding* when conservative management is warranted<sup>40</sup>. The system (Figure 3) has an upper uterine balloon approved for filling to 750 ml and a lower vaginal balloon approved for filling to 300 ml. While not yet studied in, or cleared/approved for, the setting of posthysterectomy pelvic bleeding, future research may be warranted to determine whether this device may prove effective in controlling such cases.

In summary, the pelvic pressure pack is simple to construct from commonly available medical materials, and control of hemorrhage is successfully achieved in the majority of cases. If the pelvic pressure pack fails to control bleeding, other medical<sup>41</sup>, surgical<sup>42</sup>, or interventional radiology<sup>43</sup> approaches will be necessary to ultimately control bleeding. The pelvic pressure pack should be particularly useful in developing countries where more advanced surgical skills for pelvic vascular



**Figure 3** The Belfort-Dildy Obstetrical Tamponade System, trade named the ebb™ Complete Tamponade System (Glenveigh Medical, LLC, Chattanooga, TN)

ligation and technologies, such as selective arterial embolization, are not readily available. In developed countries, the pelvic pressure pack may serve as a temporizing measure pending transport to a tertiary care facility. In the majority of instances, the pelvic pressure pack will afford transfer of the critically ill patient to a postsurgical recovery setting, where restoration of hemodynamic, thermal, hematologic and acid–base homeostasis can be accomplished.

## References

1. Dildy GA 3rd. Postpartum hemorrhage: new management options. *Clin Obstet Gynecol* 2002;45:330–44
2. Baskett TF. Emergency obstetric hysterectomy. *J Obstet Gynaecol* 2003;23:353–5
3. Eniola OA, Bewley S, Waterstone M, Hooper R, Wolfe CD. Obstetric hysterectomy in a population of South East England. *J Obstet Gynaecol* 2006;26:104–9
4. Kwee A, Bots ML, Visser GH, Bruinse HW. Emergency peripartum hysterectomy: A prospective study in The Netherlands. *Eur J Obstet Gynecol Reprod Biol* 2006;124:187–92
5. Lau WC, Fung HY, Rogers MS. Ten years experience of caesarean and postpartum hysterectomy in a teaching hospital in Hong Kong. *Eur J Obstet Gynecol Reprod Biol* 1997; 74:133–7
6. Whiteman MK, Kuklina E, Hillis SD, et al. Incidence and determinants of peripartum hysterectomy. *Obstet Gynecol* 2006;108:1486–92
7. Yucel O, Ozdemir I, Yucel N, Somunkiran A. Emergency peripartum hysterectomy: a 9-year review. *Arch Gynecol Obstet* 2006;274:84–7

\*Disclosure: As the name of the device indicates, the author of this chapter, Gary A. Dildy, MD, is one of the co-inventors (along with Michael A. Belfort, MD, PhD) of this medical device. As such, and in the interest of full disclosure, the author wishes to note that he has a personal financial interest in the device's commercialization.



8. Silver RM, Landon MB, Rouse DJ, et al. Maternal morbidity associated with multiple repeat cesarean deliveries. *Obstet Gynecol* 2006;107:1226–32
9. Rossi AC, Lee RH, Chmait RH. Emergency postpartum hysterectomy for uncontrolled postpartum bleeding: a systematic review. *Obstet Gynecol* 2010;115:637–44
10. Okogbenin SA, Gharoro EP, Otoide VO, Okonta PI. Obstetric hysterectomy: fifteen years' experience in a Nigerian tertiary centre. *J Obstet Gynaecol* 2003;23:356–9
11. Knight M, Kurinczuk JJ, Spark P, Brocklehurst P. Emergency postpartum hysterectomy for uncontrolled postpartum bleeding: a systematic review. *Obstet Gynecol* 2010;115:1306–7; author reply 7
12. Clark SL, Yeh SY, Phelan JP, Bruce S, Paul RH. Emergency hysterectomy for obstetric hemorrhage. *Obstet Gynecol* 1984;64:376–80
13. Dildy GA 3rd, Paine AR, George NC, Velasco C. Estimating blood loss: can teaching significantly improve visual estimation? *Obstet Gynecol* 2004;104:601–6
14. Stafford I, Dildy GA, Clark SL, Belfort MA. Visually estimated and calculated blood loss in vaginal and cesarean delivery. *Am J Obstet Gynecol* 2008;199:519 e1–7
15. Clark SL, Belfort MA, Dildy GA, Herbst MA, Meyers JA, Hankins GD. Maternal death in the 21st century: causes, prevention, and relationship to cesarean delivery. *Am J Obstet Gynecol* 2008;199:36 e1–5; discussion 91–2 e7–11
16. Feliciano DV, Mattox KL, Burch JM, Bitondo CG, Jordan GL Jr. Packing for control of hepatic hemorrhage. *J Trauma* 1986;26:738–43
17. Smith LG Jr, Moise KJ Jr, Dildy GA 3rd, Carpenter RJ Jr. Spontaneous rupture of liver during pregnancy: current therapy. *Obstet Gynecol* 1991;77:171–5
18. Zama N, Fazio VW, Jagelman DG, Lavery IC, Weakley FL, Church JM. Efficacy of pelvic packing in maintaining hemostasis after rectal excision for cancer. *Dis Colon Rectum* 1988;31:923–8
19. Finan MA, Fiorica JV, Hoffman MS, et al. Massive pelvic hemorrhage during gynecologic cancer surgery: "pack and go back". *Gynecol Oncol* 1996;62:390–5
20. Bach A, Bendix J, Hougaard K, Christensen EF. Retroperitoneal packing as part of damage control surgery in a Danish trauma centre—fast, effective, and cost-effective. *Scand J Trauma Resusc Emerg Med* 2008;16:4
21. Osborn PM, Smith WR, Moore EE, et al. Direct retroperitoneal pelvic packing versus pelvic angiography: A comparison of two management protocols for haemodynamically unstable pelvic fractures. *Injury* 2009;40:54–60
22. Papakostidis C, Giannoudis PV. Pelvic ring injuries with haemodynamic instability: efficacy of pelvic packing, a systematic review. *Injury* 2009;40 Suppl 4:S53–61
23. Ghourab S, Al-Nuaim L, Al-Jabari A, et al. Abdomino-pelvic packing to control severe haemorrhage following caesarean hysterectomy. *J Obstet Gynaecol* 1999;19:155–8
24. Luijendijk RW, JN IJ, Jeekel J, Bruining HA. An inflated condom as a packing device for control of haemorrhage. *Br J Surg* 1994;81:270
25. Awonuga AO, Merhi ZO, Khulpateea N. Abdominal packing for intractable obstetrical and gynecologic hemorrhage. *Int J Gynaecol Obstet* 2006;93:160–3
26. Logothetopoulos K. Eine absolut sichere blutstillungsmethode bei vaginalen und abdominalen gynakologischen operationen. [An absolutely certain method of stopping bleeding during abdominal and vaginal operations.]. *Zentralbl Gynakol* 1926; 50:3202–4
27. Maier RC. Control of postpartum hemorrhage with uterine packing. *Am J Obstet Gynecol* 1993;169:317–21; discussion 21–3
28. Katesmark M, Brown R, Raju KS. Successful use of a Sengstaken-Blakemore tube to control massive postpartum haemorrhage. *Br J Obstet Gynaecol* 1994;101:259–60
29. Johanson R, Kumar M, Obhrai M, Young P. Management of massive postpartum haemorrhage: use of a hydrostatic balloon catheter to avoid laparotomy. *BJOG* 2001;108:420–2
30. Bakri YN, Amri A, Abdul Jabbar F. Tamponade-balloon for obstetrical bleeding. *Int J Gynaecol Obstet* 2001;74: 139–42
31. Parente JT, Dlugi H, Weingold AB. Pelvic hemostasis: a new technic and pack. *Obstet Gynecol* 1962;19:218–21
32. Burchell RC. The umbrella pack to control pelvic hemorrhage. *Conn Med* 1968;32:734–6
33. Cassels JW Jr, Greenberg H, Otterson WN. Pelvic tamponade in puerperal hemorrhage. A case report. *J Reprod Med* 1985;30:689–92
34. Robie GF, Morgan MA, Payne GG Jr, Wasemiller-Smith L. Logothetopoulos pack for the management of uncontrollable postpartum hemorrhage. *Am J Perinatol* 1990;7:327–8
35. Hallak M, Dildy GA 3rd, Hurley TJ, Moise KJ Jr. Transvaginal pressure pack for life-threatening pelvic hemorrhage secondary to placenta accreta. *Obstet Gynecol* 1991;78: 938–40
36. Howard RJ, Straughn JM Jr, Huh WK, Rouse DJ. Pelvic umbrella pack for refractory obstetric hemorrhage secondary to posterior uterine rupture. *Obstet Gynecol* 2002;100: 1061–3
37. Dildy GA, Scott JR, Saffer CS, Belfort MA. An effective pressure pack for severe pelvic hemorrhage. *Obstet Gynecol* 2006;108:1222–6
38. Garrison JR, Richardson JD, Hilakos AS, et al. Predicting the need to pack early for severe intra-abdominal hemorrhage. *J Trauma* 1996;40:923–7; discussion 7–9
39. Abikhaled JA, Granchi TS, Wall MJ, Hirshberg A, Mattox KL. Prolonged abdominal packing for trauma is associated with increased morbidity and mortality. *Am Surg* 1997;63: 1109–12; discussion 12–3
40. FDA. Safety and effectiveness. [http://www.accessdata.fda.gov/cdrh\\_docs/pdf9/K091958.pdf](http://www.accessdata.fda.gov/cdrh_docs/pdf9/K091958.pdf)
41. Bouwmeester FW, Jonkhoff AR, Verheijen RH, van Geijn HP. Successful treatment of life-threatening postpartum hemorrhage with recombinant activated factor VII. *Obstet Gynecol* 2003;101:1174–6
42. Clark SL, Phelan JP, Yeh SY, Bruce SR, Paul RH. Hypogastric artery ligation for obstetric hemorrhage. *Obstet Gynecol* 1985;66:353–6
43. Vedantham S, Goodwin SC, McLucas B, Mohr G. Uterine artery embolization: an underused method of controlling pelvic hemorrhage. *Am J Obstet Gynecol* 1997;176:938–48