

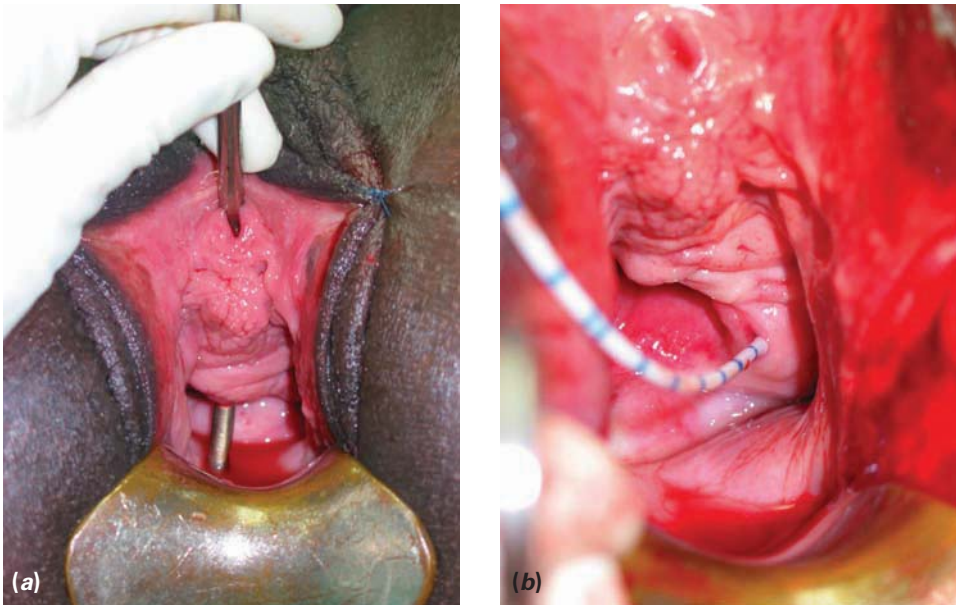Figure 6.29 (a,b) This is a large fistula high in the vagina and involving the cervix (Goh's type 1cIII). When fully exposed after an episiotomy, the ureteric orifice is seen on the edge of the fistula. This would be quite easy for an expert, but a novice could get into difficulty.

JUXTA-URETHRAL AND CIRCUMFERENTIAL FISTULAE

The following are discussed in this section:

- Management of juxta-urethral and circumferential fistulae
- Management of ureteric involvement.

The key to repair of the more complex fistulae is to understand the circumferential fistula.

Anyone reading standard textbook accounts of vesico-vaginal fistula repair may get the impression that the fistula is simply a hole in the base of the bladder that needs to be closed transversely in one or two layers. The concept of circumferential loss and the strategies for dealing with this are often glossed over.

In the majority of cases, the ischaemic injury occurs at the urethro-vesical junction. When there is complete separation of urethra and bladder, the defect is called circumferential. If the urethra and bladder are still together to some extent, the defect is, by tradition, called juxta-urethral.

The degrees of circumferential loss are illustrated in Figure 6.30. It must be appreciated that in the larger defects the antero-lateral bladder wall is adherent to the pubic rami. The practical point is to make the distinction between fistulae with a

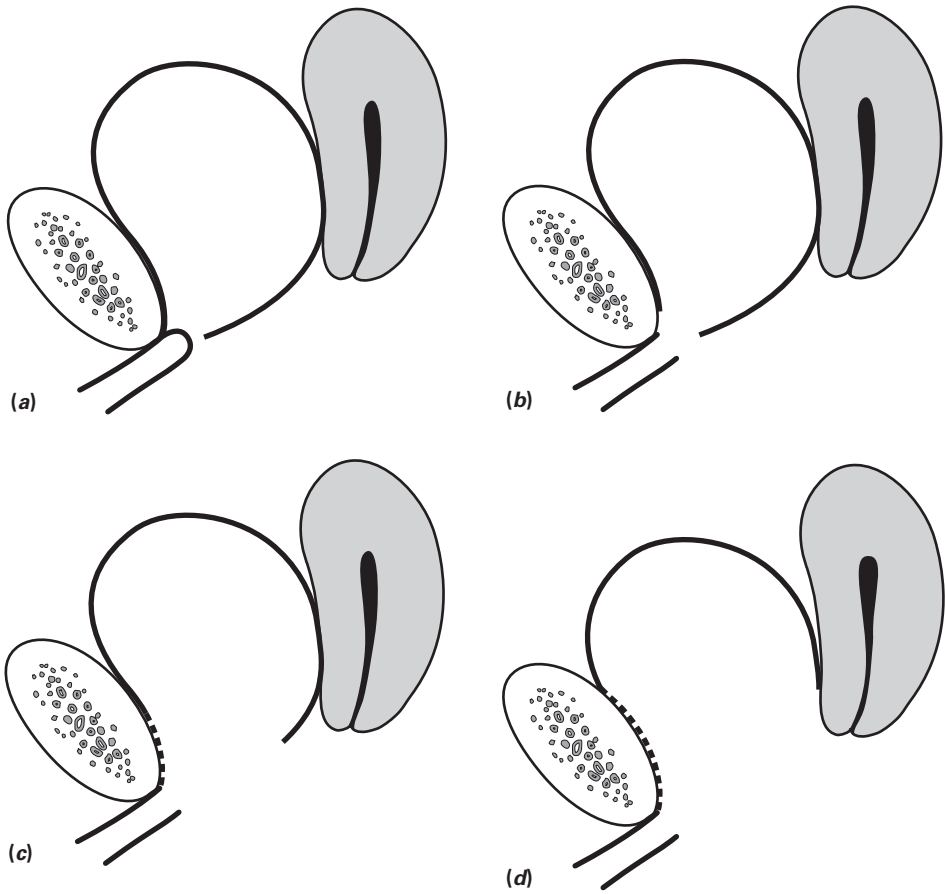


Figure 6.30 Degrees of circumferential tissue loss: (a) stenosed proximal urethra but negligible separation; (b) complete separation with a small gap; (c) more separation with pubic bone exposed – most of the anterior vaginal wall is missing; (d) major separation with significant loss of bladder volume.

small or negligible gap and those with a significant gap, as the management is different. In juxta-urethral fistulae, there is no complete separation. The defect extends around just part of the circumference of the bladder neck region and appears as a simple hole on inspection. The varying degrees of loss are shown in Figure 6.31.

There are two important things to consider:

- To what extent is there circumferential tissue loss (i.e. separation of bladder and urethra)?
- How much urethra has been destroyed?

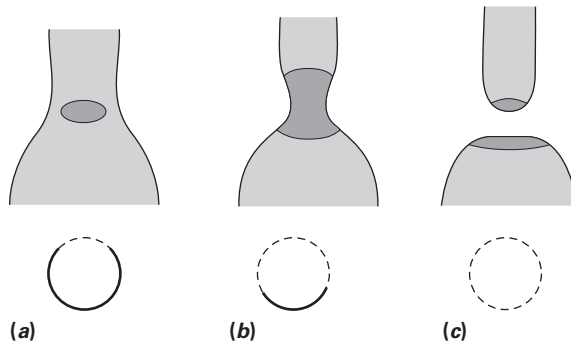


Figure 6.31 Degrees of incomplete detachment: (a) one-quarter loss; (b) three-quarters loss; (c) complete detachment. In the bottom row, the heavy shading indicates the muscle and mucosa remaining.

Extent of circumferential tissue loss

Is the circumferential tissue loss partial or complete? Many partial defects extend only around the superficial one-quarter and are easily closed by transverse sutures. In other cases, the defect extends around the sides, and the continuity between urethra and bladder is maintained on the deep aspect, where it is lightly adherent to the undersurface of the pubic arch. Here a three-quarters to one-half circle anastomosis of bladder to urethra is required. There will usually be no major discrepancy in size between urethra and bladder neck.

Where there is complete separation, a gap will be felt and seen. A circumferential re-anastomosis is generally recommended.

Extent of urethral destruction

The normal urethra is about 3.5 cm long. The urethra is almost always damaged to some extent in the cases under discussion. There is frequently a block in the proximal urethra, which needs to be dilated. The status of the urethra is best recorded by measuring or estimating the distance from the external urethral orifice to the distal fistula margin (it is helpful to know the length of one's own distal phalanx and length from nail tip to nail bed. Goh's classification from 1 to 4 may then be applied. Urethral length is the major prognostic factor for stress incontinence. When the urethra is short, we recommend a urethral support procedure that is described later in this chapter.

Operative steps for non-circumferential fistulae

A non-circumferential fistula in the region of the bladder neck

Figure 6.32 illustrates a common simple juxta-urethral fistula, with less than a half-circumferential defect.

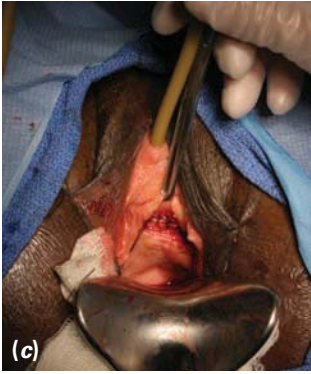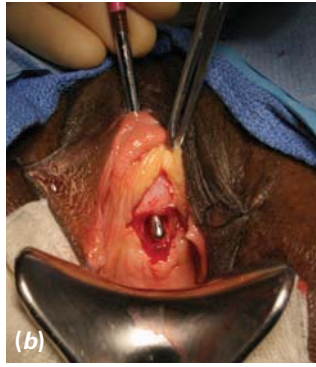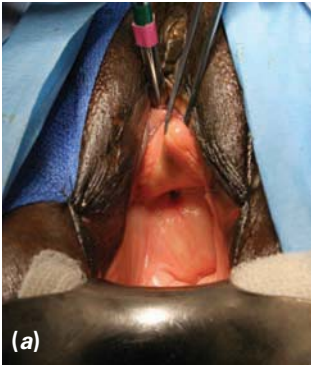
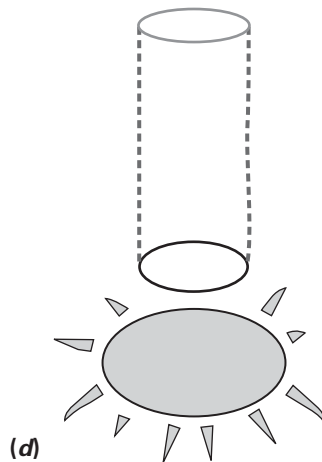
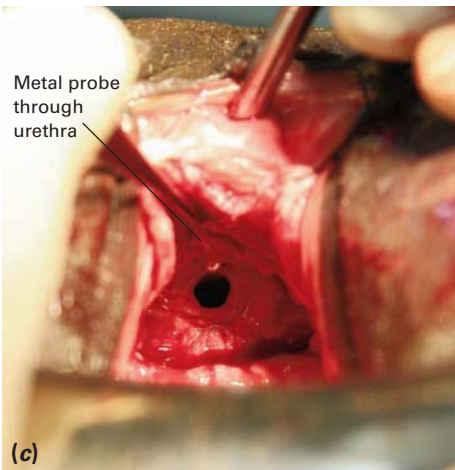


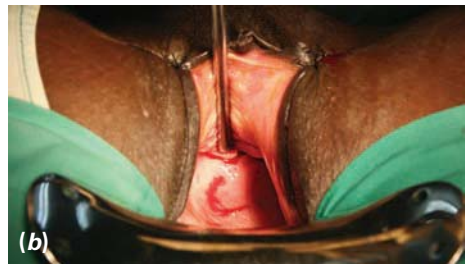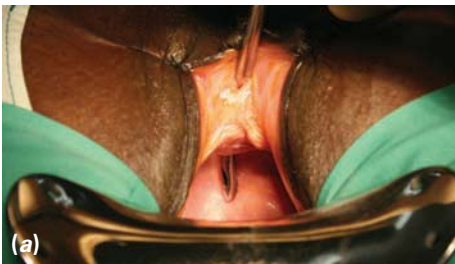Figure 6.32 (a) As is often the case, the fistula is somewhat pulled up behind the symphysis. Head-down tilt of the operating table is essential for access. (b) The vaginal flaps have been reflected and the defect exposed. The distance from the external urethral orifice to the fistula is 3 cm. (c) The repair has been completed in one layer.



Continued

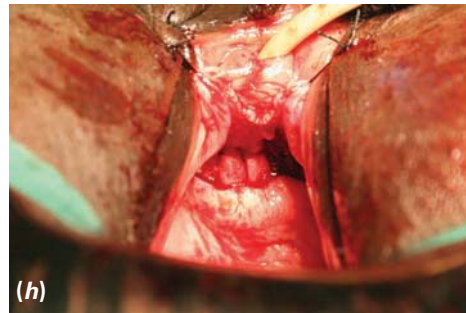
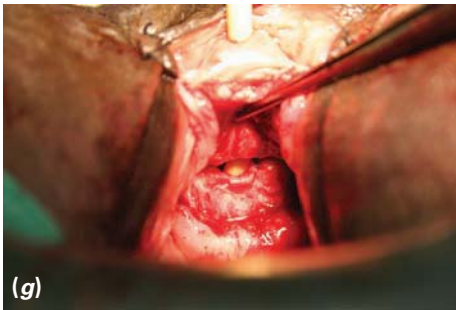
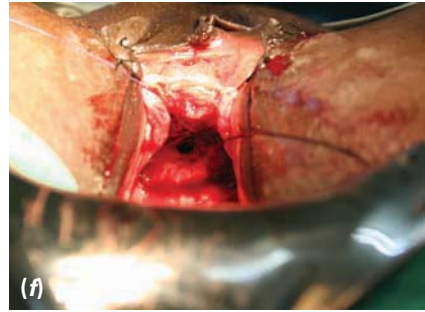
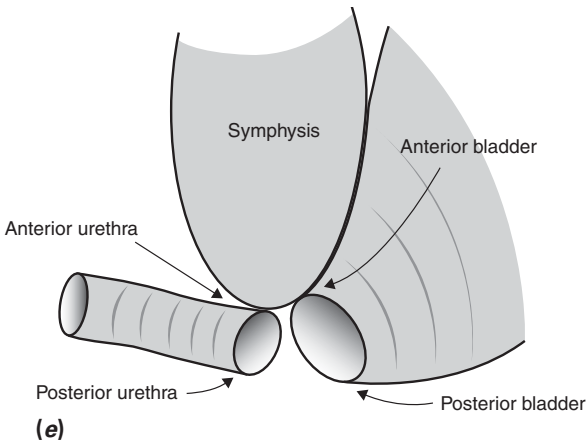


Figure 6.33 (a) The fistula is out of sight, being tethered behind the pubic bone. (b) After tilting the table, the defect is best exposed by placing the metal catheter through the fistula into the bladder. The first incision has been made. (c) The vaginal flaps have been separated. The hole seen is the entrance to the bladder. The metal catheter is in the urethra and can be just seen coming through the proximal end (arrowed). The bladder and urethra are just together on the deep aspect. (d) The surgeon's view of the defect. (e) A side view of the defect (for clarity, anterior and posterior are as indicated in this diagram). (f) A three-quarter anastomosis has been started by placing the two corner sutures at 2 and 10 o'clock. (g) Sutures have been placed at 3 and 9 o'clock, and the remaining posterior defect can be clearly seen over a catheter. (h) The anastomosis has been completed in one layer.

An almost-circumferential juxta-urethral fistula

A larger juxta-urethral fistula that is almost circumferential is shown in Figure 6.33.

Vertical closure

Another strategy for the non-circumferential bladder neck fistula is to consider vertical closure of the defect (Figure 6.34). This is possible only in about 10% of cases. The defect must be soft and mobile, and there must be no tension. Vertical closure will effectively increase urethral length, and may improve the prospect of continence.

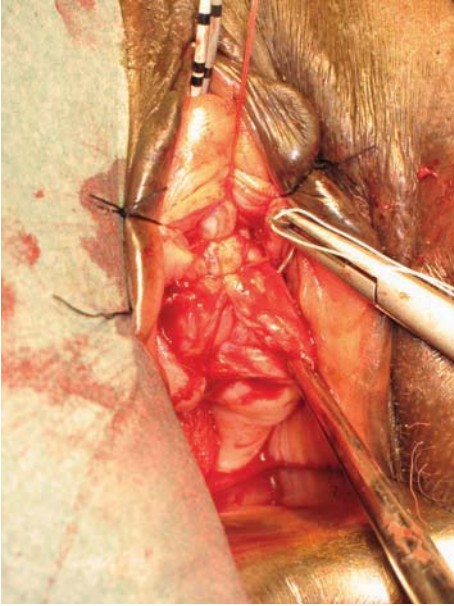


Figure 6.34 Vertical closure of a soft mobile juxta-urethral/mid-vaginal fistula.

Operative steps for circumferential fistulae

Where there is a clear separation of urethra and bladder, there are two options for repair:

- Incomplete mobilization and suture of the bladder to the pubic rami and urethra, leaving a gap on the anterior aspect.
- Complete mobilization of the bladder front, back and sides, followed by circumferential anastomosis to the urethra using a variety of methods to accommodate any discrepancy of size of the two ends. Where possible, an effort is made to reduce the diameter of the bladder where it is anastomosed to the urethra.

Incomplete mobilization

Incomplete mobilization (Figure 6.35) has, historically, been the method used to repair circumferential fistulae in the Addis Ababa Fistula Hospital, and is still practised by some surgeons trained there. The bladder is mobilized from the vagina and cervix only over its posterior and lateral aspects, until sufficient mobility has been obtained to bring the bladder directly to the antero-lateral boundaries of the bladder defect. This is, in effect, the undersurface of the pubic rami lateral to the urethra. Before this is done, a distal flap of vaginal epithelium will have been reflected off the pubic rami and urethra. Strong, small half-circle needles are needed to fix the bladder to the periosteum. The urethra is incorporated into this repair as the last step.

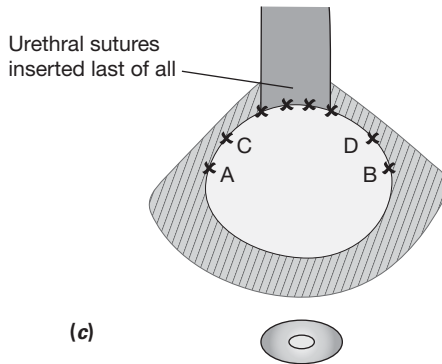
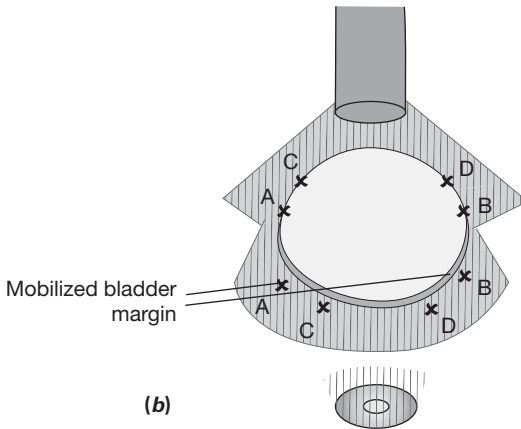
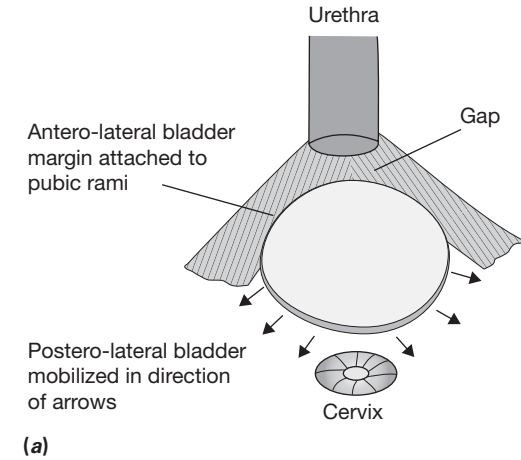


Figure 6.35 (a) Mobilization is only done postero-laterally (note that the ureters must be catheterized). (b) The mobilized bladder margin is sutured to the periostium/para-urethral area as indicated by the letters. (c) The urethral sutures are inserted last, using the centre of the posterior mobilized bladder.

Advantages of incomplete mobilization

- The operation may be easier to perform than a complete detachment and anastomosis. This will appeal to the novice surgeon or one working in difficult circumstances.
- A high rate of closure can be obtained.

Disadvantages of incomplete mobilization

- Stress incontinence may be unacceptably high.
- There is no muscle between the urethra and bladder on the anterior aspect and the urethra remains short.
- If the fistula breaks down in the corners (the most common place), the margin of the defect will be bone – an almost impossible situation to re-repair.
- Secondary operations for stress are often needed, and may be hazardous. The bladder immediately proximal to the urethra will have its anterior wall as a thin membrane of urothelium directly over the posterior symphysis. There is a risk of producing another fistula with a urethral and bladder base plication or with a rectus fascial sling operation. Opening the para-vesical space is a step used in many operations for stress.

Complete mobilization

The alternative of complete mobilization and circumferential anastomosis is recommended by most fistula experts, and is now increasingly used in the Addis Ababa Fistula Hospital.

After the usual posterior and lateral mobilization, the para-vesical space is freely entered. The bladder is dissected free of the pubic rami and symphysis. The retro-pubic space is entered, and the anterior bladder wall is freed so that it can be pulled down easily to reach the urethra. Sometimes, a suture may be placed from the anterior wall to the back of the pubis to hold the bladder in place before beginning the anastomosis.

The anterior aspect of the urethra will be adherent under the symphysis. Scar in this region is excised, but no attempt is made to mobilize the urethra. The posterior and lateral aspects will already have been exposed by careful elevation of the distal vaginal flaps.

If the bladder opening is not too large and the urethra not short, the anastomosis can be completed end to end by bunching up the bladder side to make it fit. The anterior and two antero-lateral sutures are placed first, followed by two corner sutures – all of these take in a good bite of peri-urethral tissue. The posterior sutures are placed accurately through the urethral lumen. It is most important that bladder mucosa does not protrude through the suture line. Bites should be taken that invert the bladder mucosa.

Often, a mismatch between the diameter of the bladder opening and that of the urethra makes a straight end-to-end anastomosis impossible. The underlying principle in closure is to use the anterior and lateral bladder to wrap around the urethra and then to close the excess posterior bladder vertically. This has the effect of making the bladder lumen into a tube before joining the urethra. In the largest defects, this is not possible, because the postero-lateral margin containing the ureteric orifices cannot be mobilized enough to meet in the midline. The finished repair will then resemble an inverted 'V' or 'Y' (Figure 6.36). This also has the advantage of keeping the ureteric orifices in a more physiological position in relation to the new urethro-vesical junction.

Advantages of complete mobilization

- The urethro-vesical junction is now completely surrounded by muscle, and in many cases the bladder defect will have been converted to a tube, thus effectively lengthening the urethra. The incidence of postoperative stress incontinence may be reduced.
- A secondary stress operation can be more safely performed if required.

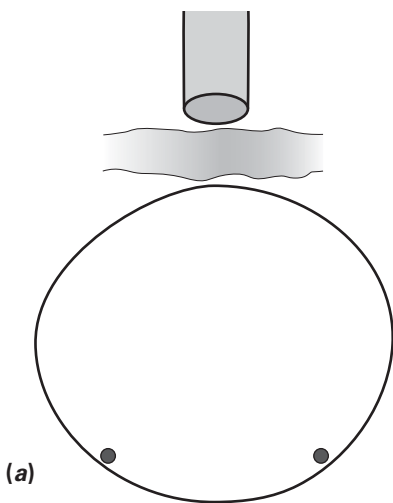
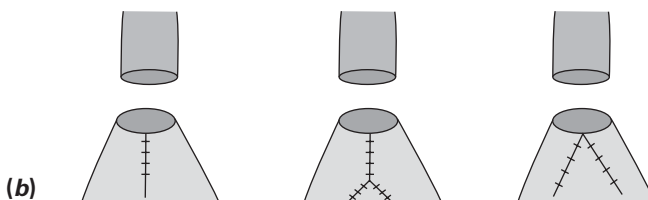


Figure 6.36 (a) A typical large circumferential defect. There is a large discrepancy in size between the bladder defect and the urethra. (b) The three methods of matching the bladder to the urethra. Note that the anterior and lateral sutures are inserted before dealing with the excess posterior bladder.



Disadvantages of complete mobilization

- The anastomosis is technically more demanding, and if not well done may be more prone to break down.

A complete mobilization illustrated

In the case shown in Figure 6.37, there is a small gap between the urethra and bladder (more evident on palpation than inspection). The bladder will be detached from the back of the pubis. There is only a slight discrepancy in size between urethra and bladder lumina.

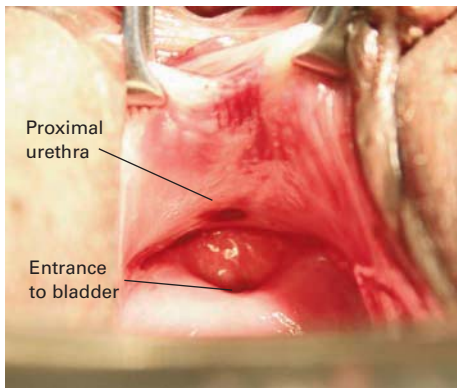


Figure 6.37 (a) The proximal urethra is seen detached from the bladder.

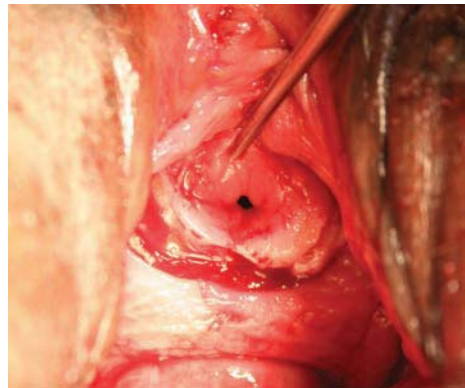


Figure 6.37 (b) The bladder has been mobilized all round and the anterior bladder is pulled down to demonstrate its mobility.

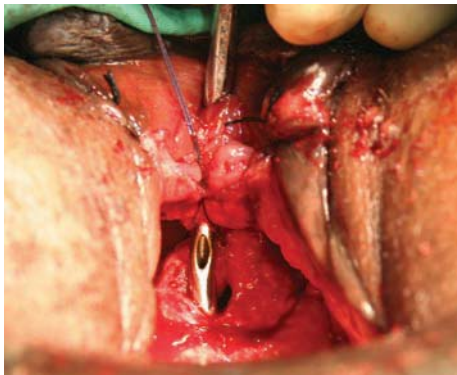


Figure 6.37 (c) The anterior (12 o'clock) midline suture has been inserted. The knot will be inside the lumen. Note the metal catheter through the urethra.

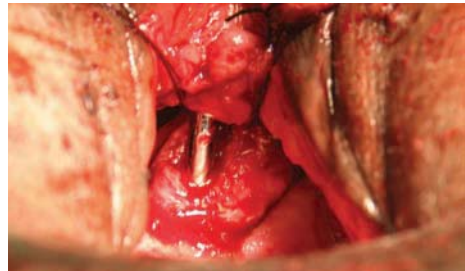


Figure 6.37 (d) Two antero-lateral sutures (2 and 10 o'clock) have now been inserted.
Continued

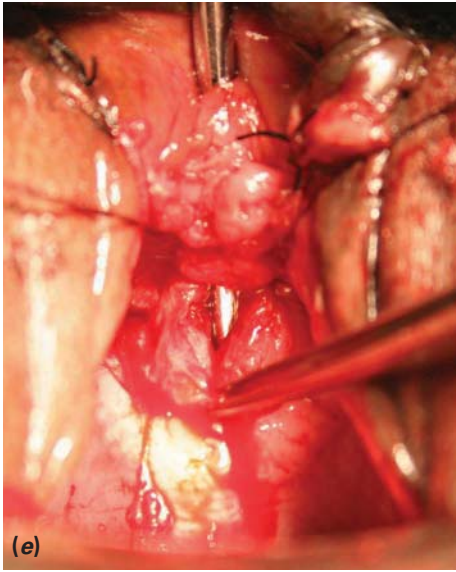
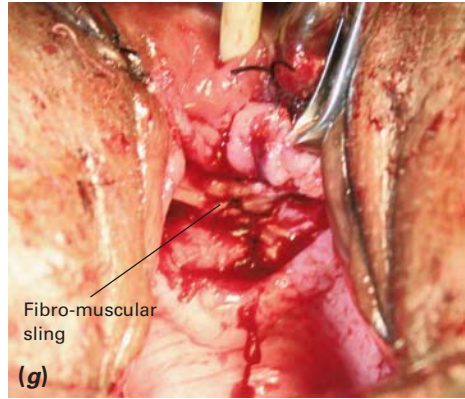
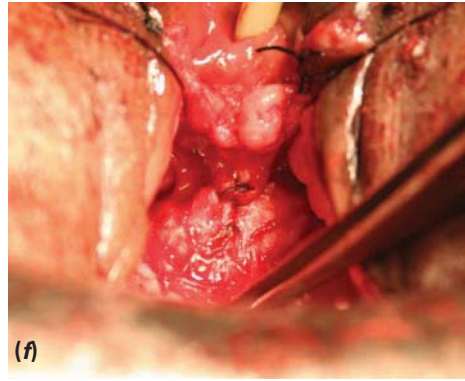


Figure 6.37 (e) The posterior half of the anastomosis remains to be sutured. (f) The anastomosis is completed using a small vertical extension because of the discrepancy in size. (g) Because the urethra was less than 2.5 cm in diameter, a fibro-muscular sling has been made.



Circumferential anastomosis

Figure 6.38 shows an example of circumferential anastomosis in a large fistula.

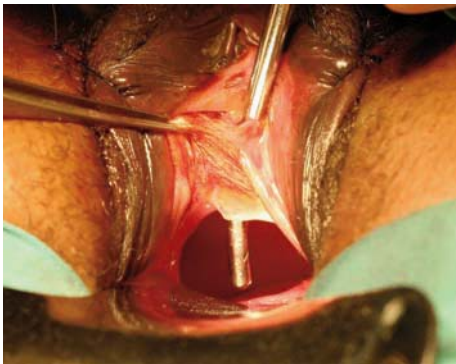

Figure 6.38 (a) A large circumferential fistula with a 2.5 cm urethra.

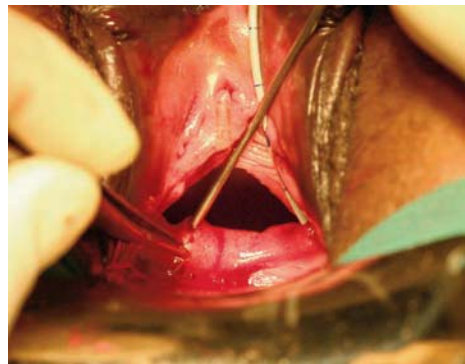


Figure 6.38 (b) The left ureteric orifice has been catheterized and the right has been identified with a probe.

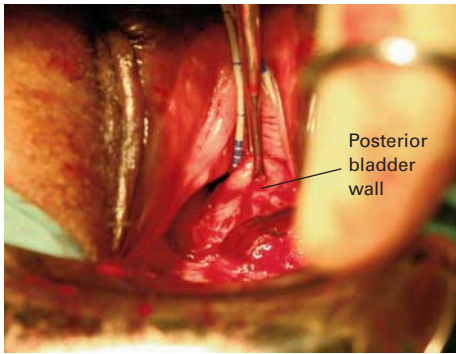


Figure 6.38 (c) The posterior bladder margin is held up as it is mobilized off the vagina and cervix.

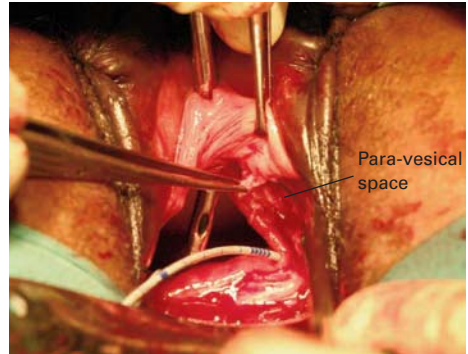


Figure 6.38 (d) The para-vesical space is entered on the left. Then the distal vaginal flap is elevated.

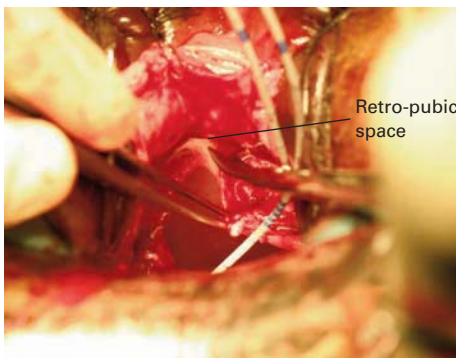


Figure 6.38 (e) The left antero-lateral bladder is dissected from the pubic rami.

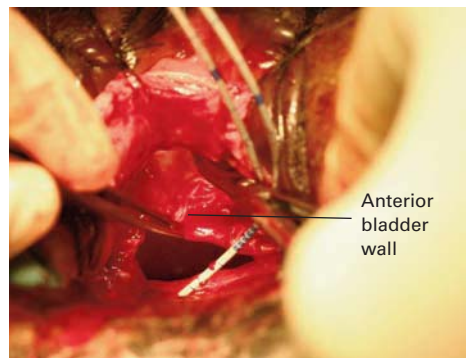


Figure 6.38 (f) The scissors are entering the retro-pubic space to free up the anterior bladder wall.

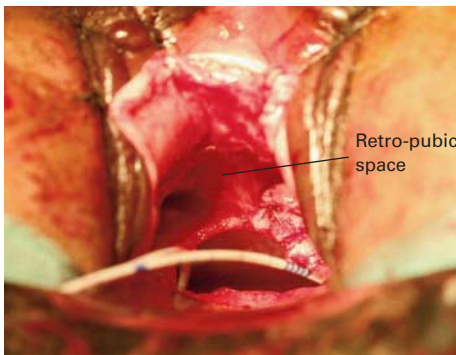


Figure 6.38 (g) The retro-pubic space is open and the anterior bladder wall is mobile.

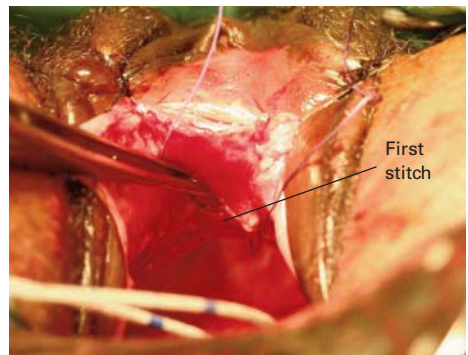


Figure 6.38 (h) The first suture has been placed into the periosteum adjacent to the anterior aspect of the urethra.

Continued

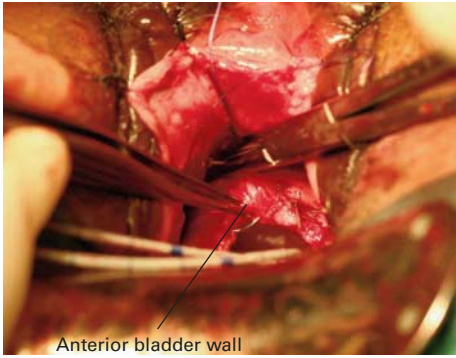


Figure 6.38 (i) Now a good bite is taken of the anterior bladder wall in the midline.

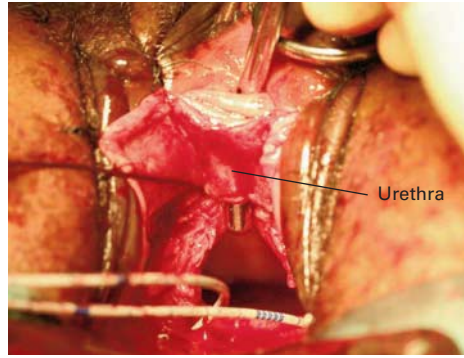


Figure 6.38 (j) The suture has been tied to approximate the bladder and urethra anteriorly (12 o'clock stitch).

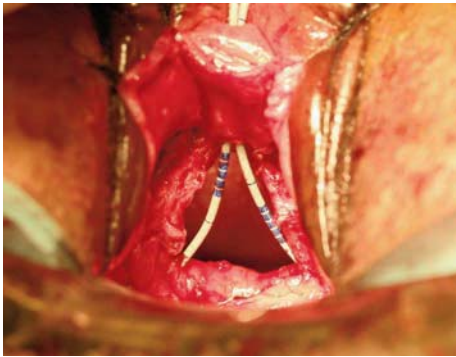


Figure 6.38 (k) Both ureteric catheters are pulled through the urethra.

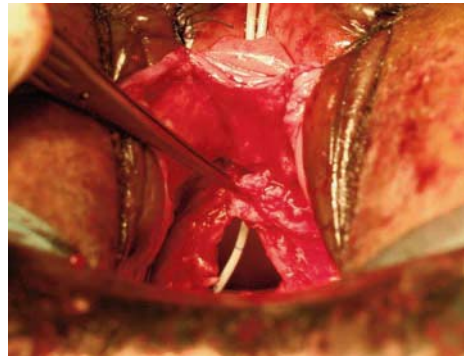


Figure 6.38 (l) The antero-lateral bladder wall is used to complete a circumferential anastomosis.

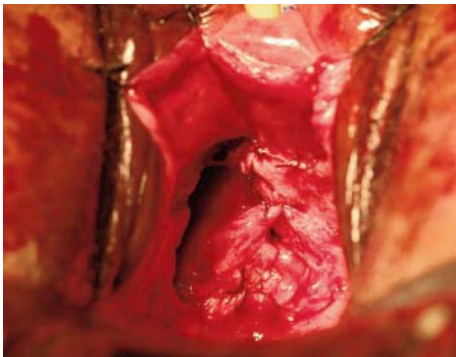


Figure 6.38 (m) The remaining bladder is closed vertically.

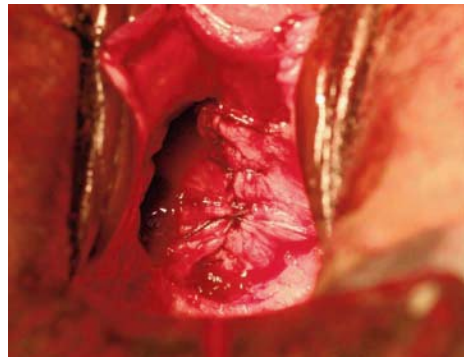


Figure 6.38 (n) The anastomosis is now complete.

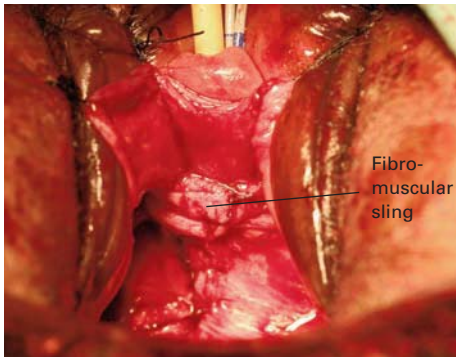


Figure 6.38 (o) A fibro-muscular sling of pubo-coccygeus is added to support the urethra.

Incomplete versus complete mobilization

Unfortunately, there are no hard data to allow a comparison of closure and incontinence rates between the two methods, but the consensus of opinion among the most experienced fistula surgeons is that a complete detachment and anastomosis does give better results. It makes sense to restore muscular continuity between bladder and urethra front and back.

It must be appreciated that, although the anastomosis can be easily performed in some cases as shown in our illustrations, in many others (which are almost impossible to photograph) the operation is quite demanding and requires a high degree of skill and judgement. It is probably only full-time fistula surgeons who have the experience to achieve good results with this group, as illustrated in a published series by Andrew Browning.¹ In a consecutive series of 321 new patients, 24% were classified as having circumferential fistulae. Of these 77 cases, 5 were inoperable as there was no bladder to repair. Of the 72 operated upon, the breakdown rate was 2.7%, but stress incontinence was high at 47%. In many, it was mild, and others were dry with a urethral plug. Almost all the circumferential fistulae were treated by complete detachment and re-anastomosis.

I have not been able to match these results for closure in my own series, although I only classify 10% of my patients as circumferential. For these, I always used to do an incomplete detachment as I had learnt at the Addis Ababa Fistula Hospital, but over the last few years I have increasingly performed a complete detachment with circumferential anastomosis. My series is quite small and I have not yet been able to demonstrate any significant improvement in my results, but I still believe that complete detachment is the right procedure whenever possible.

For those with less experience, we believe that there is still a place for incomplete detachment, provided that the gap is not too large and there is no expert available to take on the case.

Ureteric involvement

The larger the fistula and the closer it is to the cervix, the greater is the chance of ureteric involvement (Figure 6.39). During every fistula repair, one must keep in mind the position of the ureteric orifices. For small fistulae at the bladder neck, the orifices should not be close, but it must be borne in mind that what was once a large defect involving most of the anterior vaginal wall and bladder base will have contracted in the first 3 months (Figure 6.40). Thus, the anterior wall will be short and the ureteric orifices may be close to the fistula edge, even though the defect

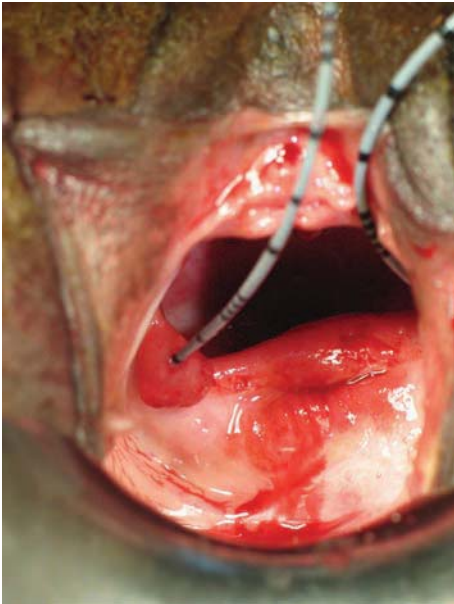


Figure 6.39 Ureter on the edge of a large fistula.

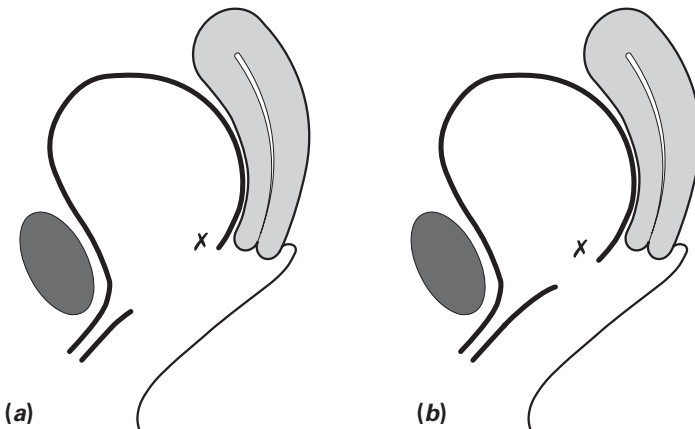


Figure 6.40 (a) Initial size of defect. (b) Size 3 months later. The cross marks the position of the ureter.

appears to start at the urethro-vesical junction. Likewise, a small defect in the region of the cervix may have been much larger at first, and subsequent contraction will have brought the ureters close to the edge of the defect.

There may be complex ureteric involvement in large circumferential fistulae. The distal end of the ureter may be involved in the ischaemic process and the uretero-vesical junction may slough away as a result, leaving the ureter draining directly into the vagina rather than into the bladder. In this case, there are three options for repair:

- If the ureter is just on or outside the edge of the bladder mucosa then, after catheterization of the ureter and sufficient mobilization of the tissues, it is possible to merely fold the ureter (containing a ureteric catheter) into the bladder as part of the repair. The ureteric catheter needs to remain in place to splint open the healing tissues for about 7 days.
- Occasionally the ureter is too far from the edge to be merely 'folded' in. In this case, it can be catheterized and then mobilized a little off the pelvic side wall. It can then be brought into the bladder at a higher level than the repair through a separate stab incision. The ureter is secured in place by 3/0 sutures through its muscularis and the bladder wall. The ureteric catheter should stay in for 12–14 days.
- Exceptionally, the ureter is too far from the bladder to be re-implanted. The options are to implant the ureter into the bladder by an abdominal approach at the same operation, or to catheterize it for 2 weeks and defer the re-implantation.

It must be appreciated that, if the last two steps are required, there is usually such severe damage that the outcomes are poor.

Other strategies for dealing with the ureters will be described in the section on juxta- and intra-cervical fistulae later in this chapter.

As stress incontinence is such a problem after repair of juxta-urethral and circumferential fistulae, some measures that can be taken to reduce its incidence are described in the next section.

OPERATIVE STEPS TO REDUCE THE INCIDENCE OF STRESS INCONTINENCE

We know the factors that predispose to incontinence from a multivariate analysis of patients in Ethiopia by Andrew Browning.² These are:

- involvement of the urethra (types 2–4 in Goh's classification) – the shorter the urethra, the greater the stress
- large fistulae
- vaginal scarring sufficient to prevent insertion of a speculum without vaginotomy

- small bladder volume post repair (<150 cm³).

Most important is loss of length and quality of urethral tissue, so any measures that can be taken to improve this should be taken. These fall into three groups:

- lengthening procedures
- repair of the pubo-cervical fascia where possible
- urethral support with a fibro-muscular sling.

Lengthening procedures

In a series of patients with severe post-repair stress incontinence from Andrew Browning, the average urethral length was 1.4 cm, which is less than half the normal length of 3–4 cm. Thus, anything that can be done to lengthen the urethra should help.

As mentioned in the section above on juxta-urethral and circumferential fistulae, it is possible in some cases to fashion the bladder side of the anastomosis into a tube with a diameter approaching that of the urethra. This is done by joining the anterior wall and sides of the bladder to the urethral remnant and closing the remaining defect in a vertical direction.

As also mentioned in the previous section, vertical closure of the defect is possible in a few cases.

Repair of the pubo-cervical fascia

The pubo-cervical fascia is a sheet that originates from the arcus tendinus on the pelvic side wall. It is a fascial sling that supports the urethra, the urethro-vesical junction and bladder base. It is disrupted by the ischaemic process, and attempts to repair this damage are worthwhile, even though it may appear insubstantial. Some surgeons make a quite extensive dissection over the bladder base to identify the fascia and pull it together in the midline, thus supporting and elevating the new urethro-vesical junction (Figure 6.41). This is really just a radical plication of the distal bladder.

Urethral support with a fibro-muscular sling (pubo-coccygeal sling)

A review by Andrew Browning of 318 consecutive patients successfully repaired at the Addis Ababa Fistula Hospital in the year 2000 showed an immediate postoperative incontinence rate of 33%. Repair was by simple closure, with a fat graft added in most cases. This was a much higher figure for incontinence than had previously been recognized, and he started to use a fibro-muscular sling in high-risk cases, i.e. those with a shortened urethra (<2.5 cm from the external urethral orifice,

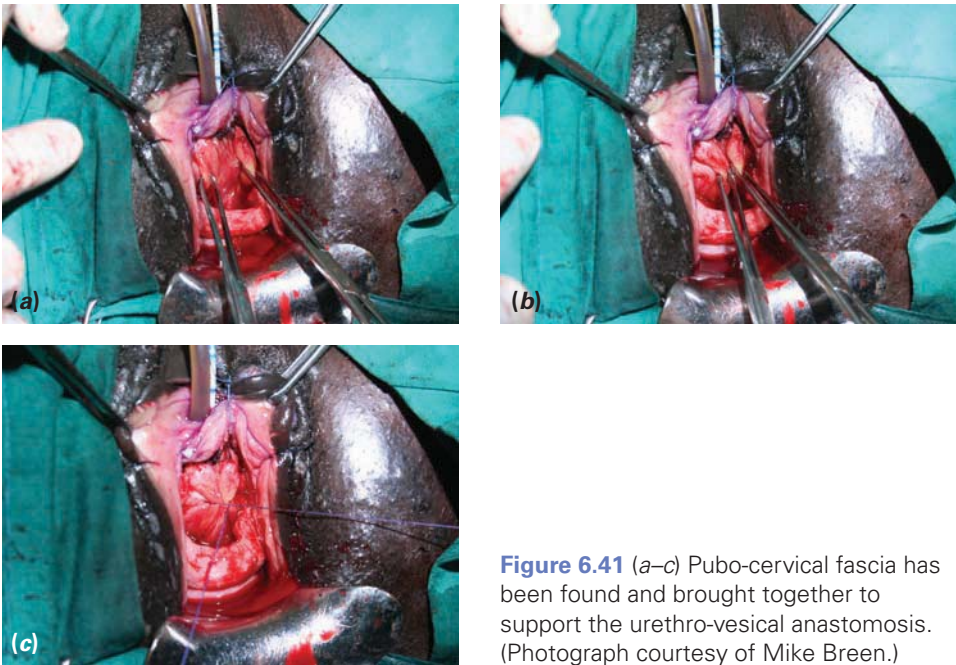


Figure 6.41 (a–c) Pubo-cervical fascia has been found and brought together to support the urethro-vesical anastomosis. (Photograph courtesy of Mike Breen.)

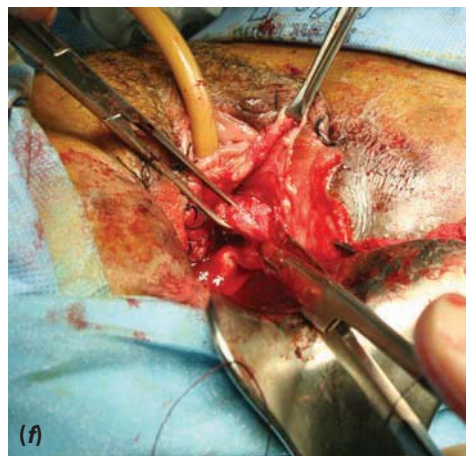
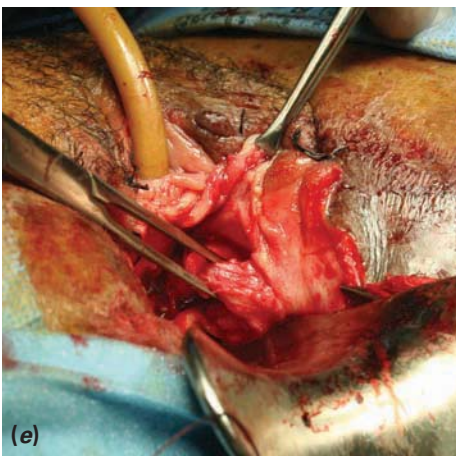
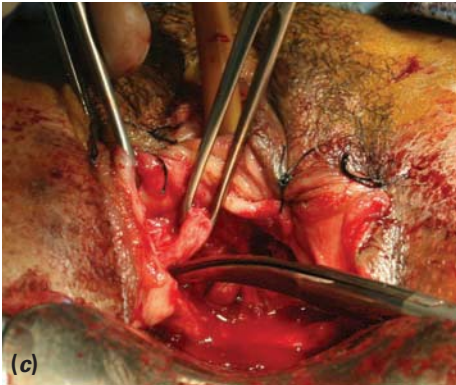
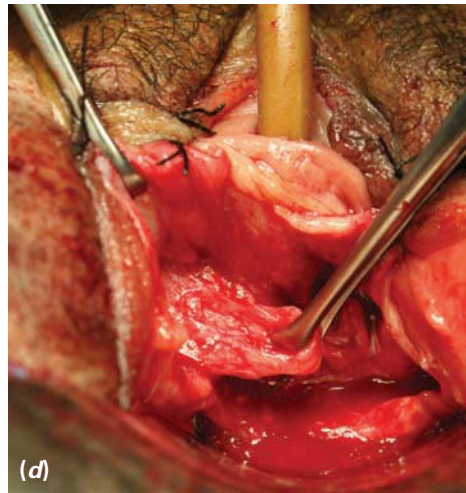
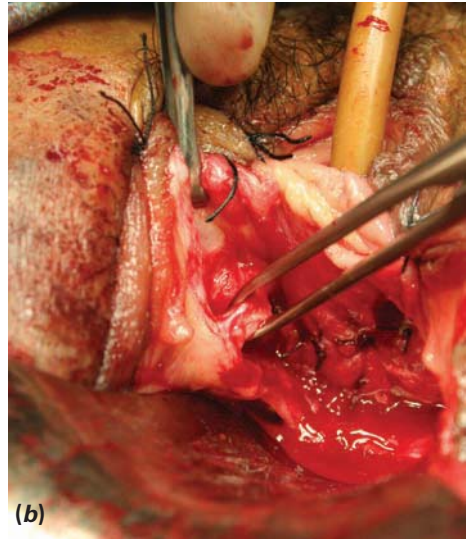
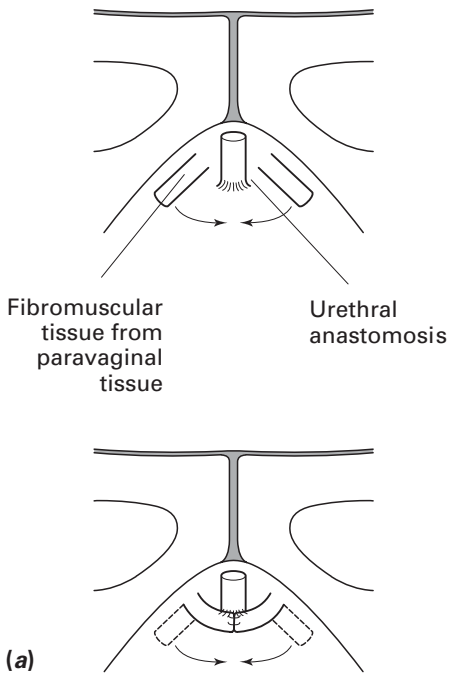
Goh's type 3 and 4). Since this was adopted in his routine practice, the rate of postoperative stress incontinence has been reduced to 18%.³

The exact nature of the tissues used to make the sling is open to debate, but is generally considered to be pubo-coccygeal muscle.

The procedure is best understood by referring to the diagram and photographs shown in Figure 6.42. The lateral ends of the vaginal incision that was made around the fistula are extended a little downwards in the axis of the vagina. The vaginal skin is elevated so as to expose some fibro-muscular tissue under the pubic rami. The belly of fibro-muscular tissue that can be felt in this area is grasped with Allis forceps. A cut is made below with scissors so as to elevate a broad rectangular block of tissue attached anteriorly under the pubic arch. The same procedure is performed on the other side, and then the two sides are sutured together in the midline beneath the urethra with two interrupted sutures. If the dissection has been taken high enough, the sling should wrap around the urethra in a gentle 'U' shape.

Unfortunately, in many of the worst cases, the pubo-coccygeal muscle has been destroyed and replaced by fibrosis. The sling will then be mostly scar, but may still give some support.

We use this sling in most patients with fistulae that are less than 2.5 cm from the external urethral orifice. We may also be influenced by the quality of the urethra, using the sling when the urethra is thin and also sometimes adding it to longer urethras when an obvious urethral leak is noticed on dye testing.



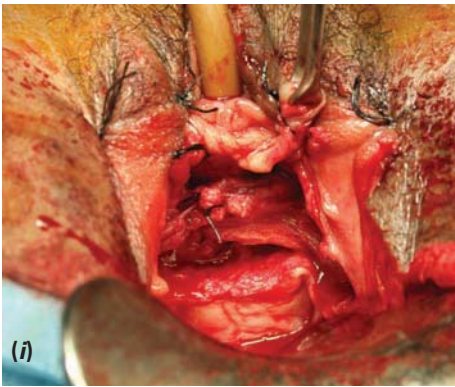
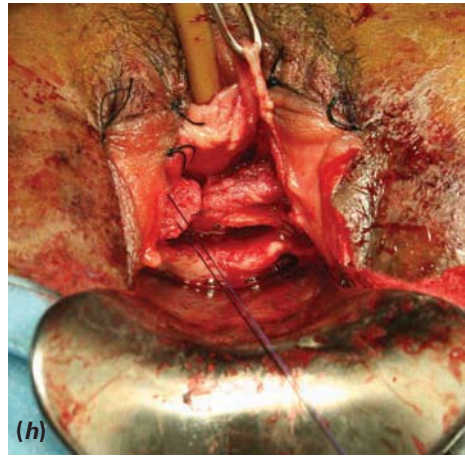
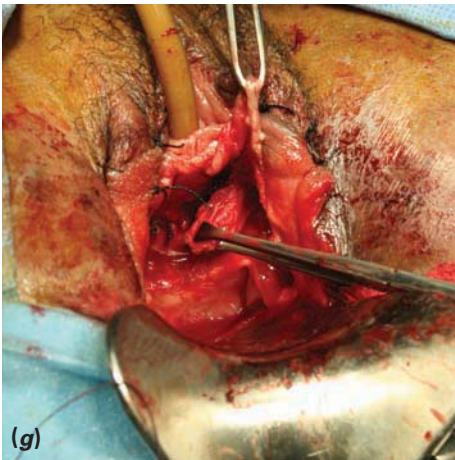


Figure 6.42 (a) Two thick strips of fibromuscular tissue are sutured together under the urethra. (b) Tissue is grasped from the lateral vaginal wall under the pubic ramus. (c, d) A block of fibromuscular tissue has been dissected out on the right-hand side. (e–g) The same procedure is performed on the left side. (h, i) The two blocks have been sutured together in the midline under the urethra. This should lightly compress the mid-urethra.

JUXTA- AND INTRA-CERVICAL FISTULAE

A fistula in the region of the cervix is often called a juxta-cervical fistula. Fistulae in this region can be divided into three main types:

1. The fistula is just distal to the cervix, and both distal and proximal margins are visible.
2. The distal margin can be visualized, but the proximal margin is out of sight in the cervical canal (the anterior lip of which is often split open)
3. The fistula cannot be seen at all, i.e. it is entirely intra-cervical.

Beginners should attempt only small juxta-cervical fistulae that can be easily exposed. The proximal margin between the fistula and the cervix must be clearly seen. Those that extend into the cervical canal can be challenging to close.

The general principle in repairing fistulae close to the cervix is to begin the flap splitting on the distal margin. This is exposed by upward traction with two Allis

forceps applied close to the distal fistula margin. The bladder wall is supported by a metal catheter through the urethra and fistula. A small vertical incision is made through the vagina down to the fistula margin and then taken round the distal margins to the sides, where a small lateral extension may be made. The antero-lateral flaps are developed, keeping just under the vaginal mucosa. It is easy to stray into the bladder wall. These flaps are then sutured up to the labia. The postero-lateral dissection towards the cervix must be carried out with extreme caution, staying just under the vagina. The ureter is very much at risk where it runs in the wall of the bladder. It should, if possible, already have been catheterized.

An easy case

A type 1 case is shown in Figure 6.43. As a general rule if the fistula is very small (<0.5 cm) and in the midline then the ureters should not be at risk. However, if one can see into the bladder then they should always be identified. Babcock forceps should be used to evert the bladder – toothed forceps cause bleeding. Intravenous furosemide 20 mg should be administered if there is still difficulty.

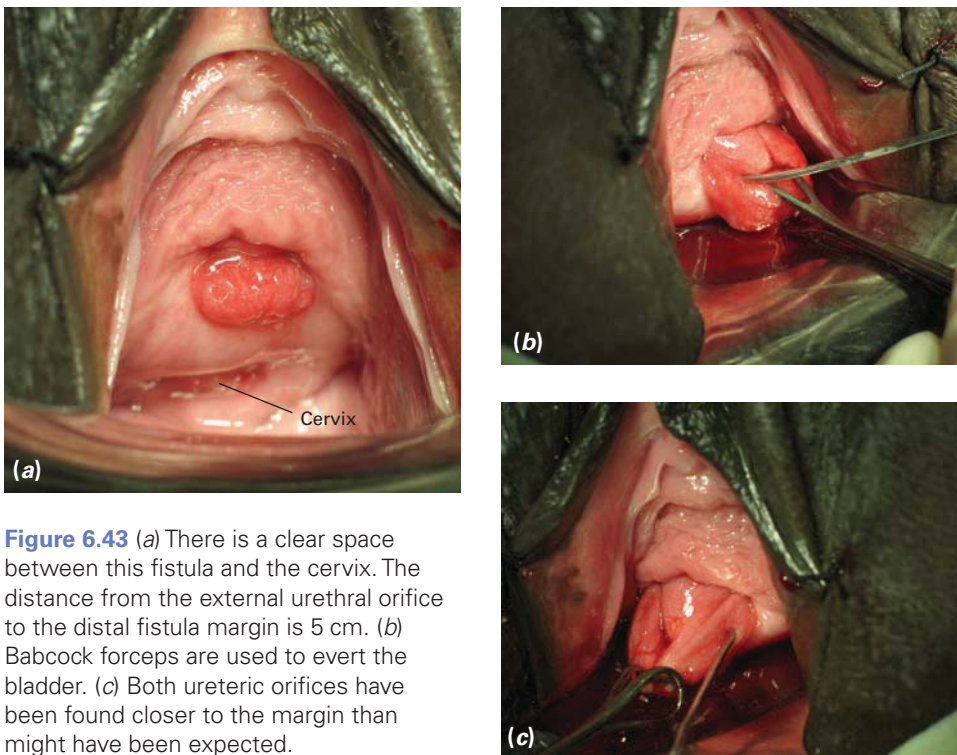


Figure 6.43 (a) There is a clear space between this fistula and the cervix. The distance from the external urethral orifice to the distal fistula margin is 5 cm. (b) Babcock forceps are used to evert the bladder. (c) Both ureteric orifices have been found closer to the margin than might have been expected.

Intermediate examples

Figures 6.44 and 6.45 show two intermediate examples.

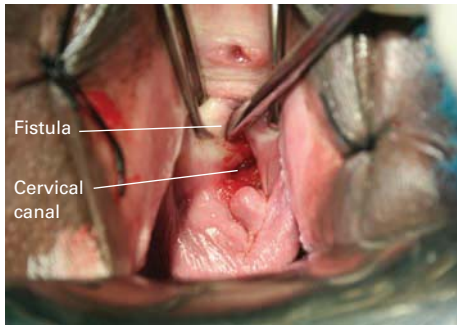


Figure 6.44 This fistula demonstrated by the metal catheter is separated from the cervical canal by a thin septum. Most of the anterior cervix has been lost.

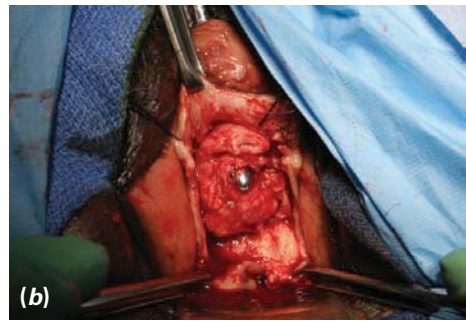
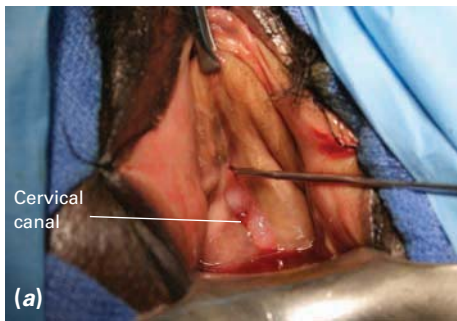


Figure 6.45 (a) This juxta-cervical fistula is very close to the cervical canal. (b) In the same case, the vagina has been reflected and the bladder dissected off the cervix to expose the small defect. It would be impossible to expose the ureters unless the defect were to be enlarged, but there is no need to do this, as the patient will not be at risk with such a small defect. It can be closed with three sutures.

Combined juxta-/intra-cervical fistulae

An example of a combined juxta-/intra-cervical fistula is shown in Figure 6.46. If the ureters are not easily found in this sort of case, a Langenbeck or Sims speculum should be used to expose the interior of the bladder (Figure 6.47).

Figure 6.48 shows a juxta-cervical fistula that extends high up into an open cervical canal. If the cervix does not come down well, cases like this can be very challenging to close and impossible to photograph. They should be left for experienced surgeons.

The incidence of this combined juxta-/intra-cervical fistula may vary from place to place. In one hospital in Uganda, 75% of fistula patients have been delivered by caesarean section, so this injury is seen quite often. Conversely, in Ethiopia, where only 15% have had a caesarean section, it is uncommon.

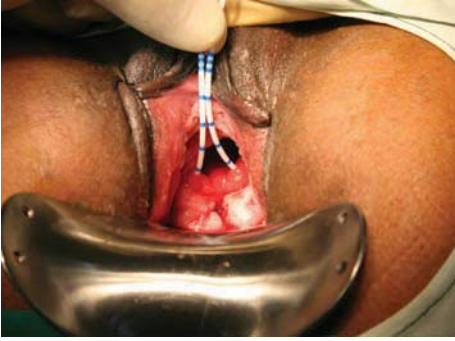

Figure 6.46 (a) The split anterior cervix can be seen. Both ureters are catheterized.

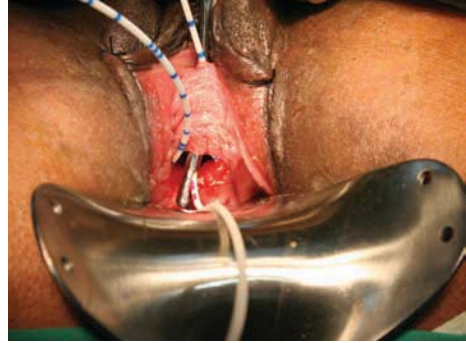


Figure 6.46 (b) The ureteric catheters are withdrawn through the urethra by passing the catheter into the eye of a metal catheter. This is an atraumatic method.

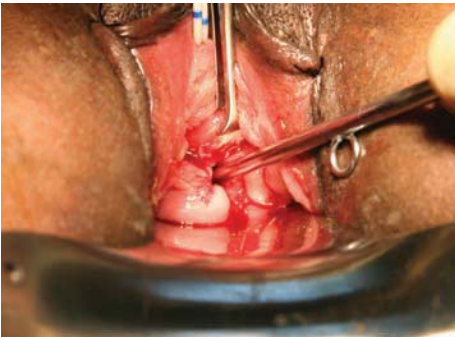


Figure 6.46 (c) To help the dissection between bladder and cervix, a metal catheter has been inserted into the cervical canal. The proximal bladder margin is held in the Allis forceps.

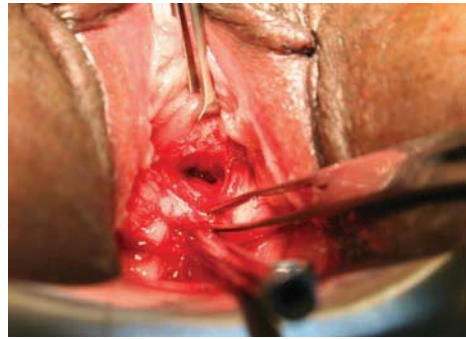


Figure 6.46 (d) The avascular plane between the cervix and bladder is opened (note the metal catheter in the cervical canal).

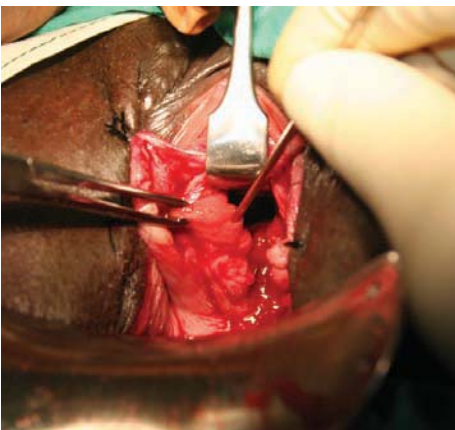


Figure 6.47 A Langenbeck retractor placed inside the fistula often aids in identification of the ureters.

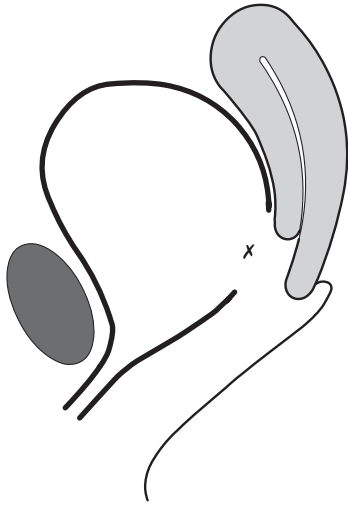


Figure 6.48 (a) A combined juxta-/intra-cervical fistula. The anterior cervical canal is missing. The approximate position of the ureteric orifice is indicated by the cross.

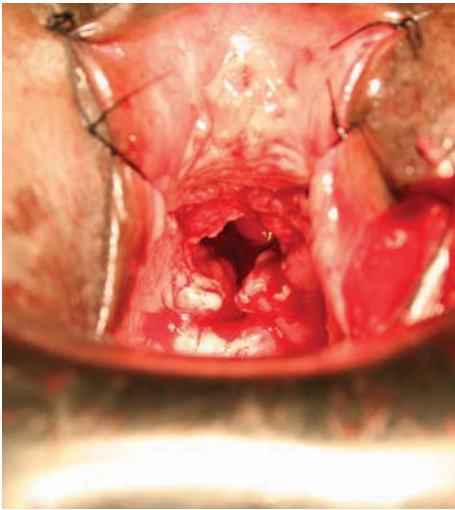


Figure 6.48 (c) The distal dissection has been completed and antero-lateral flaps sutured out of the way.

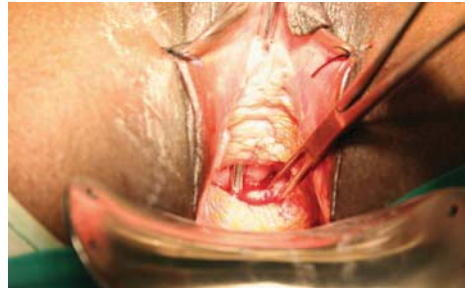


Figure 6.48 (b) Initial view. The proximal margin is far out of sight.

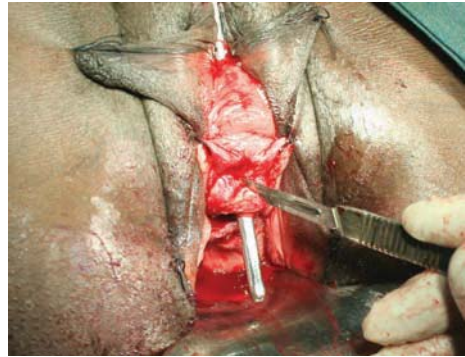

Figure 6.48 (d) The ureters are often distal to the fistula. If they cannot be found by everting the fistula margin then a cut should be made distally as shown to enlarge the fistula. The bladder defect is almost always closed vertically.

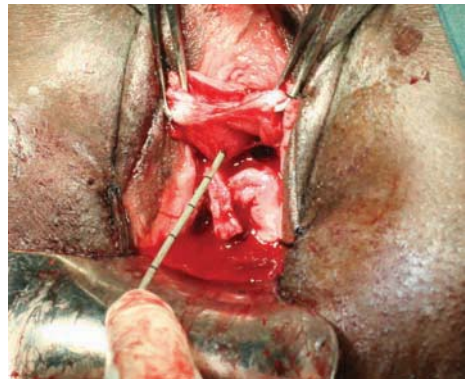


Figure 6.48 (e) The cut margins are everted to expose the ureteric orifices. It will also now be possible to insert a Sims speculum to see the proximal limit of the defect. *Continued*

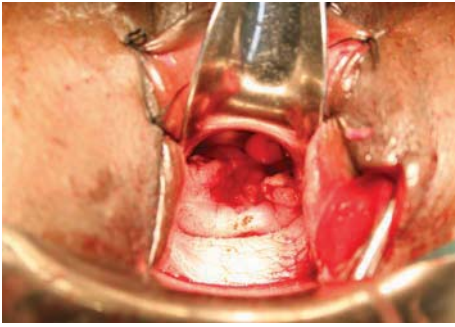


Figure 6.48 (f) A Sims speculum is placed inside the fistula to show the defect extending up the cervical canal. The latter is wide open. With the speculum in place and the ureters identified, the bladder must be dissected from the cervix up to the apex of the defect.

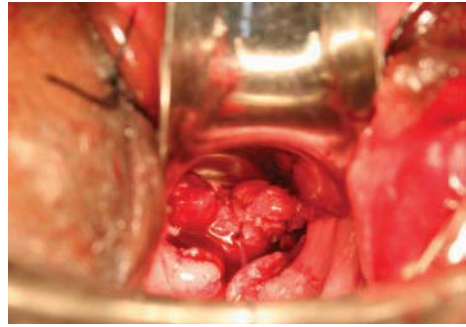


Figure 6.48 (g) The bladder margins are free, and the first suture is placed as a big bite into the apex of the defect. A continuous suture is ideal, taking good bites of bladder, mucosa and muscle, close together. If a gap is shown later by a dye test, it may be impossible to insert any more sutures. A secure closure is easier with a continuous suture than with an interrupted one. Each suture should be locked. A 5/8-circle needle is perfect in this situation – the tip of the needle is much easier to see and pick up.

Intra-cervical fistulae

Two cases of intra-cervical fistulae are shown in Figures 6.49 and 6.50. A fistula will not be seen in the vagina, and a dye test shows a leak coming through the cervix. These fistulae always result from a caesarean section; most are iatrogenic due to accidental incorporation of some bladder when closing the lower segment. Provided

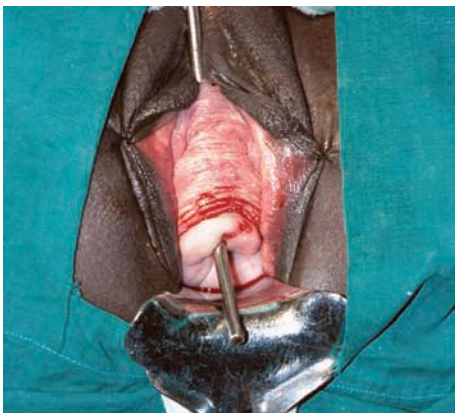


Figure 6.49 In this multiparous patient, the intra-cervical fistula is easily exposed.

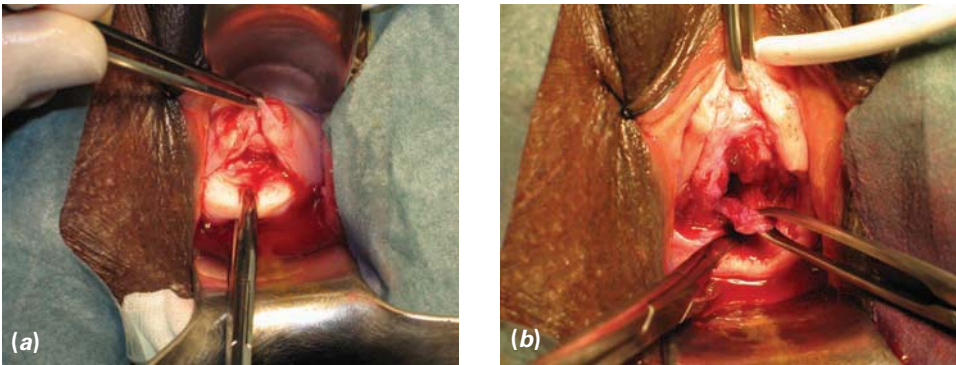


Figure 6.50 (a) In this patient, the space between the bladder and anterior cervix has been developed. (b) The defect in the bladder can now be seen, and is ready for suture. The ureters could not be found on the fistula margins, and were assumed to be safely distal to the defect.

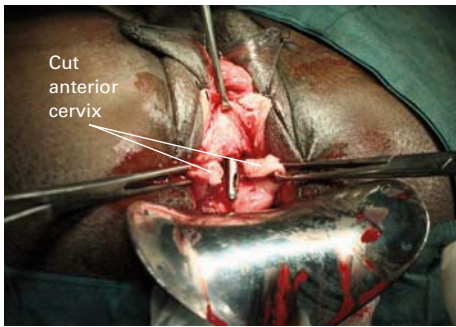


Figure 6.51 The anterior cervix has been cut through to expose the fistula. Strong downward traction on the two sides of the cervix will aid dissection of the bladder to expose the top of the fistula.

that the cervix comes down well, they are not difficult to repair from below (as in the case shown in Figures 6.49 and 6.50).

In some cases, I have found it helpful to cut vertically through the anterior cervix, with the metal catheter passing through the fistula (Figure 6.51). Strong traction on the cut margins of the cervix will bring the bladder defect into view, and it will be easier to dissect the adherent bladder beyond the defect to obtain safe closure. The hole will be well above the ureters.

Andrew Browning repairs all intra-cervical fistulae from below, but I elect to repair about one-third of those that I see via an abdominal trans-vesical approach. Those with less experience of vaginal surgery may find it easier to repair all true intra-cervical fistulae from above, although we advise them to learn the vaginal approach as soon as possible. The abdominal approach is described in the next section.